

Looking Further When Symptoms Are Disproportionate to Physical Findings

IAN SHRIER¹, DAVID R. MORRISON¹, and ROGER HAWKES²

¹Centre for Clinical Epidemiology, Lady Davis Institute, Jewish General Hospital, McGill University, Montreal, Quebec, CANADA; and ²European Tour Performance Institute, European Tour, UNITED KINGDOM

ABSTRACT

SHRIER, I., D. R. MORRISON, and R. HAWKES. Looking Further When Symptoms Are Disproportionate to Physical Findings. *Med. Sci. Sports Exerc.*, Vol. 51, No. 1, pp. 1–3, 2019. A 36-yr-old man presents with left ulnar-side wrist pain during an ice hockey game that prevented him from playing hockey or golf. There was no acute mechanism of injury. The usual clinical examination revealed only minimal tenderness and minimal pain with resisted wrist extension. Careful attention to precipitating factors led to testing resisted wrist extension with the forearm fully supinated, which reliably reproduced the intensity of the patient's symptoms, and a diagnosis of extensor carpi ulnaris tendinopathy. A literature review suggested three additional special tests (two were positive) and management. However, a standard of care has yet been established because neither the tests nor the management has been properly validated through research, thus leaving the management of this condition as an art. **Key Words:** WRIST, INJURY, FUNCTIONAL ANATOMY, TENDONOPATHY

A male athlete presented with wrist pain that prevented him from effectively playing ice hockey or golf, but the usual physical examination suggested only minimal disability. Careful attention to the anatomical position of the wrist when symptoms occurred allowed the symptoms to be reproduced with resisted testing and a diagnosis of extensor carpi ulnaris (ECU) tendinopathy and subluxation. Two of three additional tests suggested to diagnose ECU-related injuries also reproduced symptoms. The case illustrates how understanding functional anatomy can help adapt the routine clinical examination when there is a mismatch of symptoms and signs.

CASE REPORT

The patient is a 36-yr-old man who plays competitive ice hockey twice per week, and recreational golf (17 handicap).

Address for correspondence: Ian Shrier, M.D., Ph.D., Centre for Clinical Epidemiology, Lady Davis Institute, Jewish General Hospital 3755 Cote Sainte-Catherine Road Montreal, QC Canada H3T 1E2; E-mail: ian.shrier@mcgill.ca.

Submitted for publication March 2018.

Accepted for publication July 2018.

0195-9131/19/5101-0001/0

MEDICINE & SCIENCE IN SPORTS & EXERCISE®

Copyright © 2018 by the American College of Sports Medicine

DOI: 10.1249/MSS.0000000000001744

The patient first noticed ulnar sided mild left wrist pain during an ice hockey game but there was no acute injury mechanism. The pain increased the next day. X-rays were negative. The pain disappeared over 3 d but would occur sporadically during “random efforts,” such as turning a doorknob to the left. Four days after injury, the patient played ice hockey. He was unable to take a slap shot due to pain, had significant pain with backhands, some pain with wrist shots and a loss of power on face-offs. The patient rested for a week. During a golf tournament 9 d later, he had significant pain on follow through (left leading arm). In the days following golf, there was minimal pain during normal activities. When the patient attempted ice hockey again 7 d later, he was unable to effectively take a slap shot, backhand, wrist shot, or face-off. Repeat x-rays were normal. He was recommended to wear a wrist splint at all times, naproxen 500 mg twice daily and continue to rest the wrist for 10 d.

The patient was seen by the first author 4 d after the recommendation to use the wrist splint. The usual clinical examination was normal except for ulnar minimal tenderness just proximal to the ulnar styloid process, and minimal pain on standard resistance testing of ulnar deviation. There was no tenderness of any other bone or ligament, no pain with wrist compression, or pain with standard resistance testing of wrist extension, flexion, radial deviation, pronation, or supination.

The disability was disproportionate to the physical findings, and in another setting, such as a work accident, would have led to concern regarding potential secondary gain.

Reviewing the movements that triggered significant pain, the pain occurred with a slap shot, backhand, and follow-through in golf. In each motion, the forearm is fully supinated, whereas standard resistance muscle testing is done with a pronated or neutral forearm. Examining resisted wrist extension in a fully supinated position reproduced the patient's pain intensity.

A literature review suggested three special tests (1,2). The ECU Synergy test may appear counterintuitive but caused mild pain in this patient. In brief, the patient's elbow is flexed at 90° and the forearm fully supinated. With the digits extended and the wrist in neutral, the examiner asks the patient to resist the examiner's attempts to adduct the thumb. During this test, the ECU tendon contracts isometrically to stabilize the wrist. Pain is expected if the ECU tendon is injured, and the examiner may feel subluxation of the ECU if there is associated instability. The Serpent Head test represents an active contraction of the ECU but provoked only minimal pain and no tendon subluxation in this patient. In brief, the patient holds their wrist in the flexed position and the examiner rotates the wrist between full pronation and supination against resistance and looks on the ulnar side at the ECU tendon for a sudden clunk.

The Ice Cream Scoop test (2) reproduced the patient's tendon subluxation easily and repeatedly. In brief, the patient simulates the action of scooping ice cream using his/her hand. The wrist begins in pronation, ulnar deviation and extension, and the patient actively moves into full supination and flexion. In this patient, the tendon audibly and palpably subluxed, and pain occurred; this did not occur in the unaffected wrist. The original description of the test also suggests that the patient perform the motion against resistance.

A clinical diagnosis of subluxing ECU with tendinopathy was made. Ultrasonography of the affected wrist suggested normal tendon structure, mild swelling within the tendon sheath, thickened retinaculum and microcalcifications. Dynamically, the tendon subluxed as the forearm moved from pronation to supination (Fig. 1). The unaffected wrist was normal in all respects, including no subluxation.

DISCUSSION

Wrist extension and ulnar deviation failed to reproduce this patient's symptoms unless the forearm was supinated. The functional anatomy of the ECU when the forearm is not fully supinated (1) is that 1) it contributes much less to wrist extension and 2) tension on the retinaculum is much reduced. This likely led to the minimal pain in pronation, but significant pain in supination. Future research should evaluate the different special tests to determine their clinical accuracy and usefulness (sensitivity, specificity, positive and negative predictive values) in different populations.

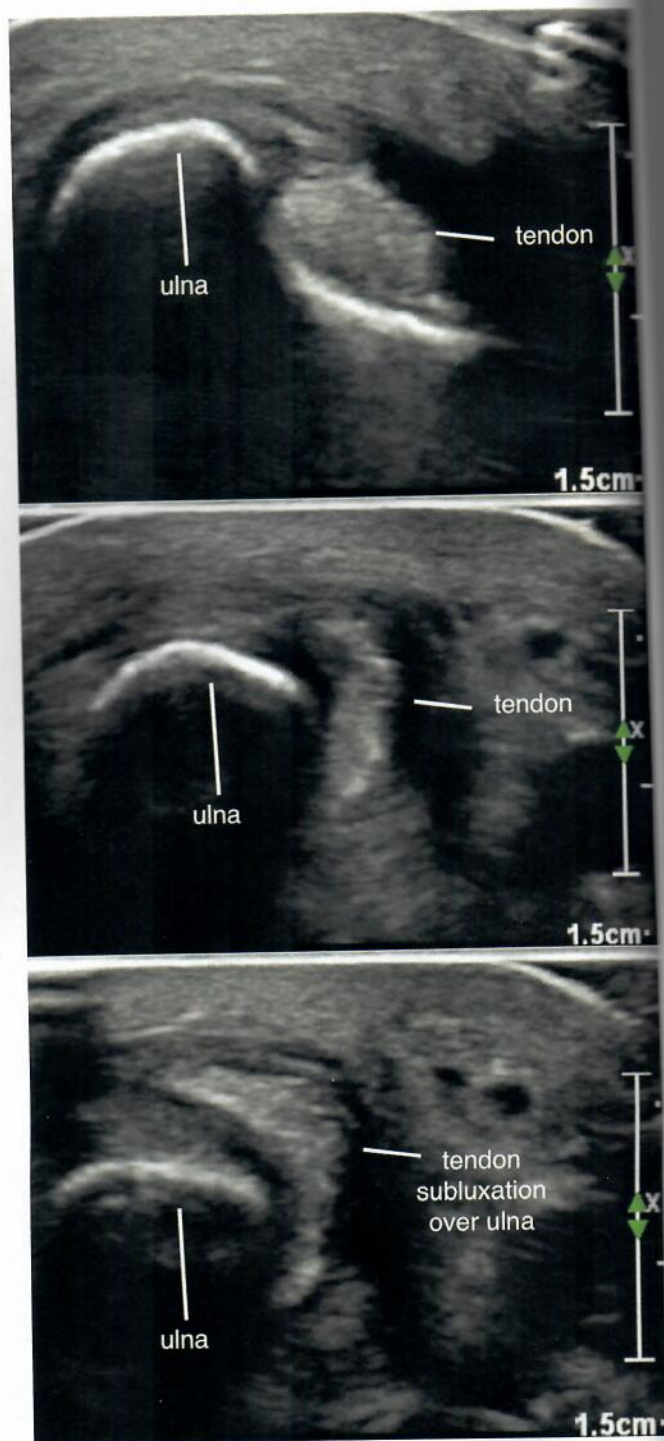


FIGURE 1—Ultrasound image of the wrist showing tendon subluxation as the wrist is moved from pronation where the tendon is in place (top), to neutral (middle, tendon moving) through to supination where the tendon is completely subluxed (bottom).

Treatment for ECU subluxation remains understudied as well (3). We did not find any studies (observational or trials) that directly compared two alternative treatments. For instability, one case series of 28 patients with ECU-related pain included 12 patients with sudden onset of symptoms

due to acute instability (our patient did not have sudden onset of pain), but reported results for only five who were immobilized for 3 to 4 months (4). We are not aware of studies reporting unilateral subluxation as an injury causing tendinopathy without an acute mechanism of injury.

Results for ECU tendinopathy treatment were reported as case reports, and one case series where 40 of 43 patients did well with repeated corticosteroid injections and/or wrist brace for 3 months (5). Surgery has also been recommended. Theoretically, wrist immobilization might be helpful if there is acute damage to the retinaculum. However, the unaffected side is often unstable as well (1), which suggests full recovery

should be possible even if instability remains. This patient opted for wrist splinting based on his own readings and recommendations from other physicians. The patient was able to return to hockey 6 months postinjury with reduced frequency of play. There is still some pain and weakness in the affected wrist.

The results of the study are presented clearly, honestly, and without fabrication, falsification, or inappropriate data manipulation. The results of the present study do not constitute endorsement by ACSM.

Conflict of Interest: The authors have no conflict of interests to report.
Source of Funding: This report was unfunded.

REFERENCES

1. Campbell D, Campbell R, O'Connor P, Hawkes R. Sports-related extensor carpi ulnaris pathology: a review of functional anatomy, sports injury and management. *Br J Sports Med.* 2013;47:1105–11.
2. Ng CY, Hayton MJ. Ice cream scoop test: a novel clinical test to diagnose extensor carpi ulnaris instability. *J Hand Surg Eur Vol.* 2013;38:569–70.
3. MacLennan AJ, Nemecek NM, Waitayawinyu T, Trumble TE. Diagnosis and anatomic reconstruction of extensor carpi ulnaris subluxation. *J Hand Surg-Am.* 2008;33A:59–64.
4. Montalvan B, Parier J, Brasseur JL, Le Viet D, Drape JL. Extensor carpi ulnaris injuries in tennis players: a study of 28 cases. *Br J Sports Med.* 2006;40:424–9; discussion 9.
5. Futami T, Itoman M. Extensor carpi ulnaris syndrome. Findings in 43 patients. *Acta Orthop Scand.* 1995;66:538–9.