ELBOW TRAUMA: CONSIDERATIONS FOR REHAB

Amber Opitz, OTR/L, CHT, CLT

ASHT Webinar

October 19th, 2024

OBJECTIVES

1. Review the types of traumatic elbow fractures and instability
2. Highlight relevant anatomy of traumatic elbow injuries
3. Discuss current available literature regarding rehabilitation for traumatic elbow injuries
4. Describe considerations and strategies for rehabilitation to optimize outcomes for traumatic elbow injuries

DISCLOSURES

None

Goal of surgical treatment of elbow trauma and instability is to restore anatomical congruency of the joint along with reconstruction of involved structures in order to create stability of the elbow.

This will allow for early motion to avoid stiffness.

As therapists, we want to progress range of motion as quickly as possible in order to get the best functional outcomes without compromising the stability of the joint achieved in surgery.

These are often case by case situations and require strong therapist/physician communication.



WHAT MAKES THIS GOAL SO DIFFICULT?

- "…competing issues of maintaining articular congruency for soft tissue healing while at the same time preventing stiffness…the elbow is prone to develop stiffness because of capsular tissues, which tend to thicken and contract when exposed to trauma" (Szekeres, et al., 2008). High congruency is needed for stabilization.
- "The elbow joint is notoriously unforgiving as even a minor nonarticular injury can cause joint contracture" (Pipicelli, et al., 2011).
- "The most common complication of elbow fractures and dislocations is the elbow flexion contracture." (Beredjiklian, 2011).
- "Fracture-dislocations of the elbow are complex injuries historically associated with unsatisfactory outcomes; however, recent improvements in both clinician knowledge of anatomy and implants/surgical techniques have created better patient outcomes" (Giannicola, et al., 2014).
- Complications: Persistent instability, malunion, nonunion, HO, stiffness/contracture, wound issues/infection, ulnar neuropathy, posttraumatic arthritis, and more (Matthew et. Al, 2009)



- Instability can be caused by:
  - Laxity
  - Dislocation of the ulnohumeral joint
  - Injury of varus and/or valgus stabilizers of the elbow
  - Injury of the radial head
- Valgus vs varus forces
  - Varus force stabilizers:
    - LCL complex, anteromedial coronoid, and extensor supinator group
  - Valgus force stabilizers:
    - UCL/MCL, radial head, anterior joint capsule (in extension), and muscles crossing the elbow (dynamic stability, flexor pronator mass/FCU/FDS)
- Posterolateral force stabilizers: Radial head and coronoid work together
- <u>Dynamic stability:</u>
  - Muscles cross the elbow provide dynamic constraint by compressing the joint when they contract
  - Tension in the biceps and brachialis muscles create a posterior vector force, which is counteracted by the coronoid and radial head creating a joint reaction force

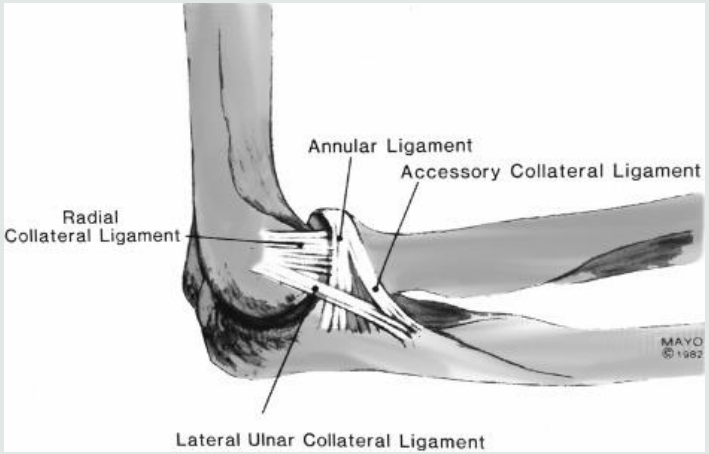

Szekeres et al., 2008 and Wolff & Hotchkiss, 2006

Broekhuis, et al., 2016 and Cohen, 2011





ELBOW STIFFNESS

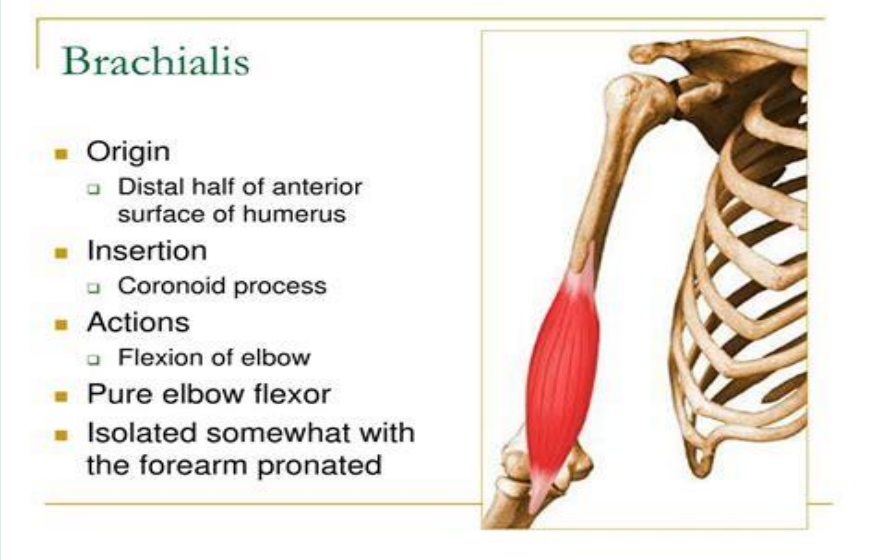

- Properties of the capsule make it sensitive to the chemical irritant of blood and effects of trauma. Fibrosis of the tissues result.
- The brachialis muscle belly lies right over anterior capsule. During trauma, this muscle tears and bleeds, a hematoma develops, and scarring and adhesion to the anterior capsule result.
- Hypertrophic collagen fibrils with extensive cross-linking can be up to 3-4mm thick and can block elbow flexion and extension (Beredjiklian, 2011). This can occur in just a few days post-injury (Davila & Johnston-Jones, 2006).
- Intra-articular pressure is lowest at 70-80 degrees of flexion

Altman, E., 2011 &
Davila, S.A., 2011.

DISTAL HUMERUS FRACTURES

- "Recent trends for early mobilization of elbow fractures and/or dislocations postinjury/postoperatively have improved outcomes" (Beredjiklian, 2011).
- "Intra-articular distal humerus fractures are severely disabling injuries, particularly in the elderly population… in addition to the complex articular anatomy of the distal humerus, fixation is often challenging because of fracture comminution and osteopenic bone" (Huang, et al., 2011).
- Several studies have demonstrated good outcomes in ORIF of distal humerus fractures in the elderly, others have demonstrated hardware failure and poor outcomes in up to 25% of patients.

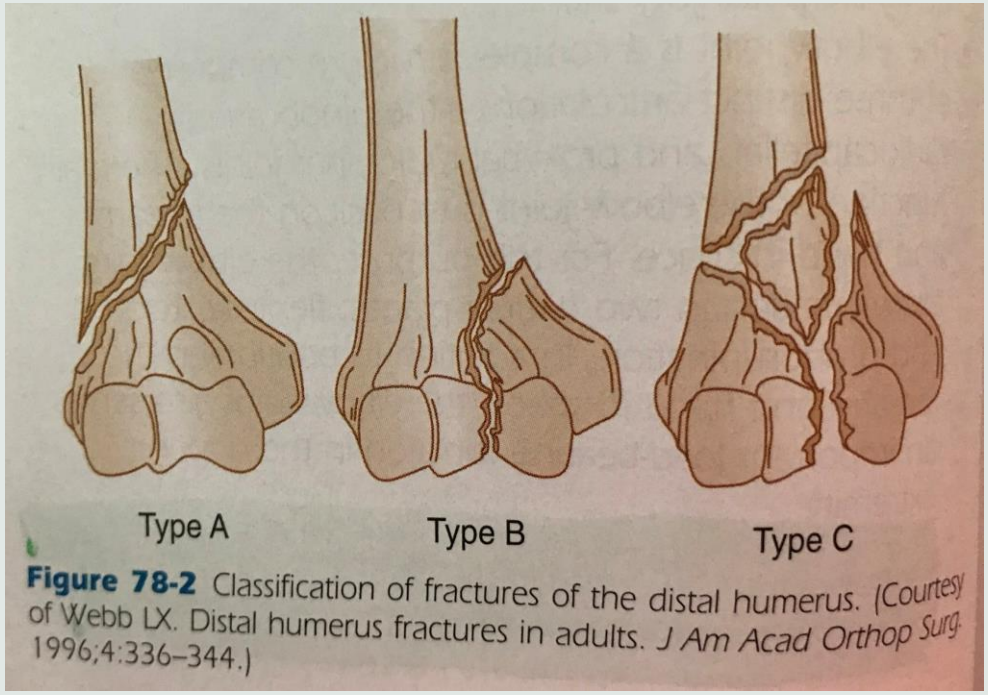

Figure 78-2 Classification of fractures of the distal humerus. (Courtesy of Webb LX. Distal humerus fractures in adults. *J Am Acad Orthop Surg.* 1996;4:336–344.)

ELBOW DISLOCATION

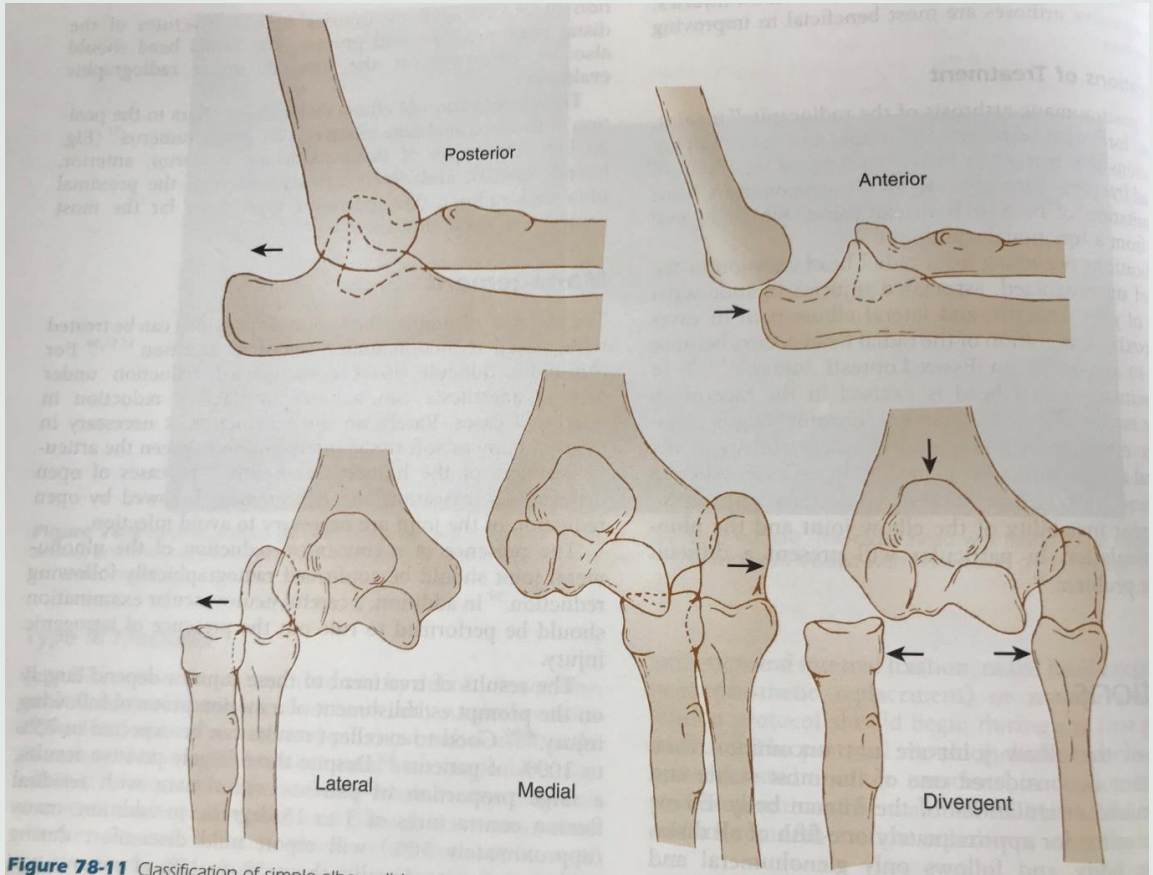

Figure 78-11 Classification of simple elbow dislocations. (Courtesy of Jupiter JB, Mehne DK. Fractures of the adult elbow. In: Browne Levine AM, et al, eds. *Skeletal Trauma*. Philadelphia: WB Saunders; 1992.)

- Mechanism of injury is most commonly forceful fall on outstretched hand
- Classification refers to the position of the proximal ulna relative to the distal humerus
  - Posterior is the most common type
- What to expect?
  - (Beredjiklian, 2011) Good to excellent outcomes in 75-100% of patients
  - Residual flexion contracture of -5 to-15 degrees
  - Mild discomfort with loading activities reported in 50% of patients
  - 5-15% of patients will report mild loss of strength in the affected extremity

Szekeres et al., 2008

RADIAL HEAD FRACTURES AND CONSIDERATIONS FOR REHAB(CANNON, 2020 & BEREDJIKLIAN, 2011):

- Type 1 fracture:
  - Non-op
  - Immobilization in sling for 1 week or less
- Type 2 fracture:
  - Short period of immobilization followed by early ROM protocol
  - Non-op as long as no mechanical block to motion resulting from the radial head fracture fragment
  - If displaced, ORIF or excision of radial head if there is a mechanical block to motion; also depends on demands of the patient
- Type 3 fracture:
  - Excision (controversial due to poor outcomes) or radial head arthroplasty
- Recommended initiation of rehab is within the 1st week (ideally 3-5 days) post-op, assuming good fracture fixation. Consider starting in mid range of motion and gradually increasing arc of motion.
- Important to examine the wrist for a Essex-Lopresti lesion
- Delay impact sports (tennis, golf, lacrosse, hockey, football, basketball, volleyball) x 4 months
- Complications: Decreased ROM, posttraumatic arthrosis of the radiocapitellar joint, nonunion, HO, wrist pain/loss of grip strength/lateral elbow pain when Essex-Lopresti lesion is unidentified and radial head migrates proximally

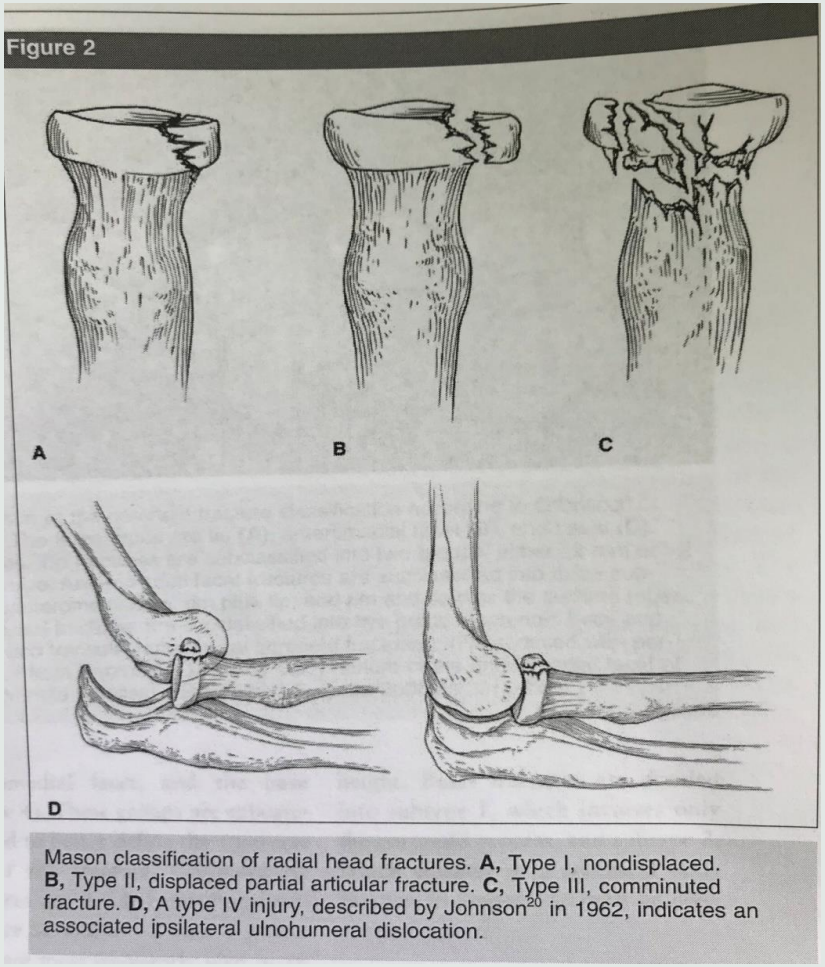

Mason classification of radial head fractures. **A,** Type I, nondisplaced. **B,** Type II, displaced partial articular fracture. **C,** Type III, comminuted fracture. **D,** A type IV injury, described by Johnson[20] in 1962, indicates an associated ipsilateral ulnohumeral dislocation.

- Matthew et al, 2009

CORONOID FRACTURE CLASSIFICATION

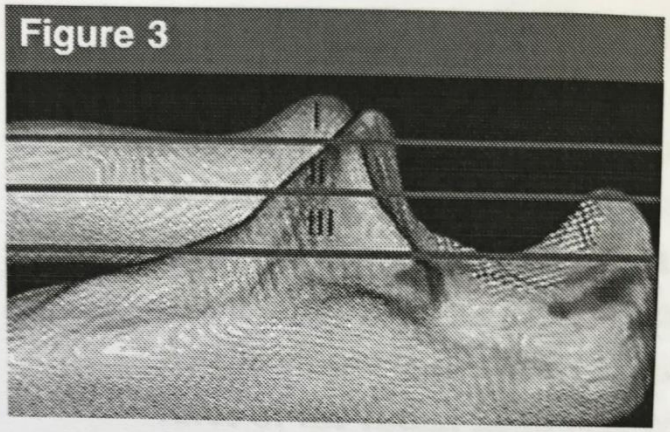

Coronoid fracture classification developed by Regan and Morrey.[22] Type I fracture, avulsion of tip of coronoid process; type II, fracture involving ≤50% of the coronoid process height; type III, fracture involving >50% of the coronoid process height. (Reproduced with permission from Doornberg JN, Ring D: Coronoid fracture patterns. *J Hand Surg [Am]* 2006;31:45-52.)

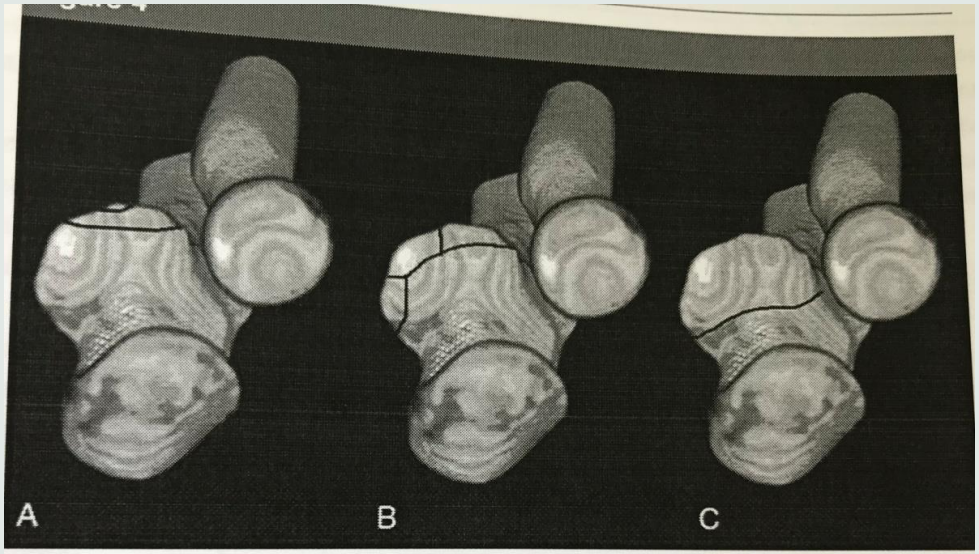

Illustration of the coronoid fracture classification according to O'Driscoll et al.[28] The three types are tip **(A)**, anteromedial facet **(B)**, and basal **(C)** fractures. Tip fractures are subclassified into two groups, either ≤2 mm or >2 mm in size. Anteromedial facet fractures are subclassified into three subtypes (anteromedial rim, rim plus tip, and rim and tip plus the sublime tubercle). Basal fractures are subclassified into two groups (coronoid body and base, and transolecranon basal coronoid fractures). (Reproduced with permission from Doornberg JN, Ring DC: Fracture of the anteromedial facet of the coronoid process. *J Bone Joint Surg Am* 2006;88:2216-2224.)

Matthew et al, 2009

THE TERRIBLE TRIAD…

- "Complex elbow instability is one of the most troublesome pathologies that orthopedic surgeons have to face" (Cohen, 2011).
- Combination of an elbow dislocation (often posterolateral), a radial head or neck fracture, and a coronoid process fracture
    - LCL AND/OR UCL/MCL commonly affected
- Occurs with FOOSH with valgus, axial, and posterolateral rotary forces
- "The optimal rehabilitation of terrible triad injuries is unknown" (Matthew, et al., 2009).
- Extended postoperative periods of immobilization are associated with significant functional impairment.

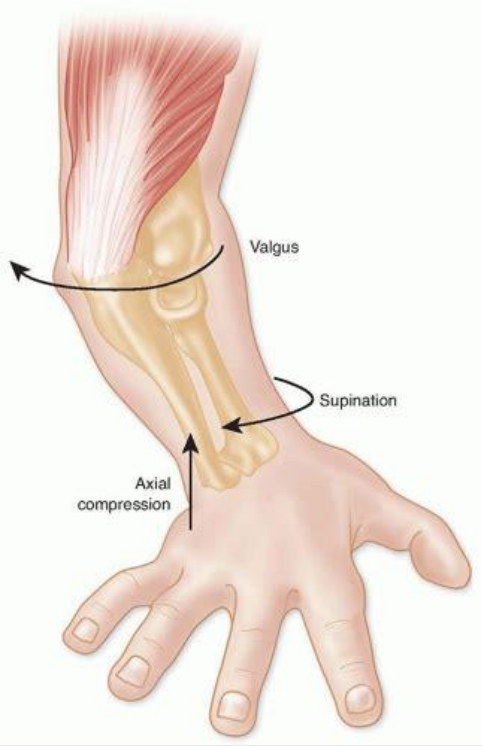

https://musculoskeletalkey.com/wp-content/uploads/2016/07/C21-FF4-4.gif

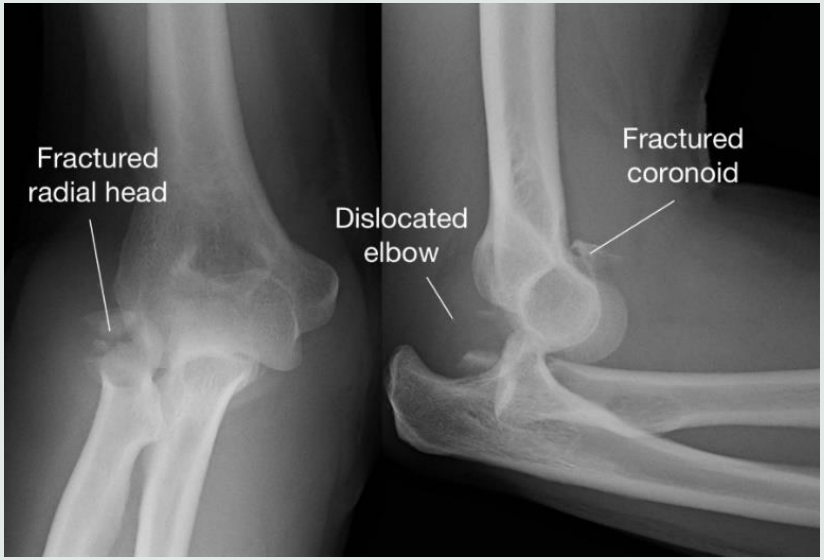

https://shoulderelbow.org/2017/07/19/terrible-triad-elbow-fracture-dislocation/

THE TERRIBLE TRIAD…

- Surgical intervention can include:
  - ORIF (screws, plate, tension band wires, pins) of the radial head/neck
  - Radial head replacement arthroplasty (if radial head is comminuted >3 fragments, involves more than 1/3 of the articular surface of the radial head with >2mm displacement, presents subacutely)
  - Radial head excision
  - ORIF of the coronoid fracture (when the fracture fragment >10% of the coronoid)
  - LCL and/or MCL/UCL reconstruction
  - +/- ulnar nerve procedure (usually used for 4 weeks)

- Outcomes:
  - Pugh and McKee, 2002: 20-135 flex/ext arc and 135 degrees of rotation with 25% of patients requiring revision surgery for residual instability, stiffness, or removal of hardware
  - Forthman et al., 2007: Ulnohumeral arc of motion 117 degrees on average with 137 degrees of rotation
  - It is normal for these patients to have some level of persistent pain for up to 6 months

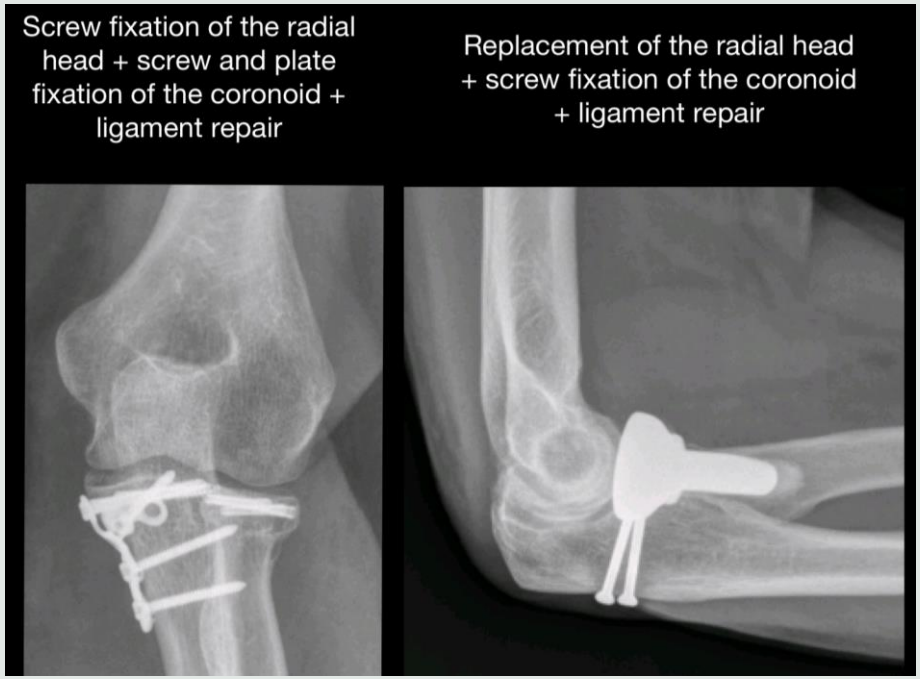

WHY EARLY ROM?



Muscles that promote stability by creating a compressive force:

Biceps
Triceps
Brachialis



The role of flexor pronator group and extensor supinator group in elbow stability



"It is well documented that early motion nourishes the cartilage and enhances soft tissue healing" (Wolff & Hotchkiss, 2006).

Broberrg and Morrey, 1987: Immobilization for >4 weeks produced consistently poor results

PROTOCOL FOR LATERAL ELBOW INSTABILITY: NONOPERATIVE AND OPERATIVE

- MD Robert N. Hotchkiss and OTR/CHT Aviva L. Wolff published this article/protocol in 2006 in the Journal of Hand Therapy.
  - Their goal in publishing this article was to provide a way for hand surgeons and therapists to safely begin early range of motion for the unstable elbow to preserve as much range of motion as possible while maintaining adequate stability of the joint.

PROTOCOL FOR LATERAL ELBOW INSTABILITY: NONOPERATIVE AND OPERATIVE

- Weeks 0-3 (as early as post op day 2): protected range of motion phase (allow stabilizing structures to heal during stage I of tissue healing)
  - Patient to be splinted in 120 degrees of elbow flexion for approximation of radial head against the coronoid and patient can remove for exercises 3-5 times per day
  - They recommended the wrist be included in neutral to relax the proximal wrist muscular attachments and increase patient comfort.
    - For LCL involvement, full pronation
    - For MCL/LCL, neutral
    - For MCL, supination



PROTOCOL FOR LATERAL ELBOW INSTABILITY: NONOPERATIVE AND OPERATIVE

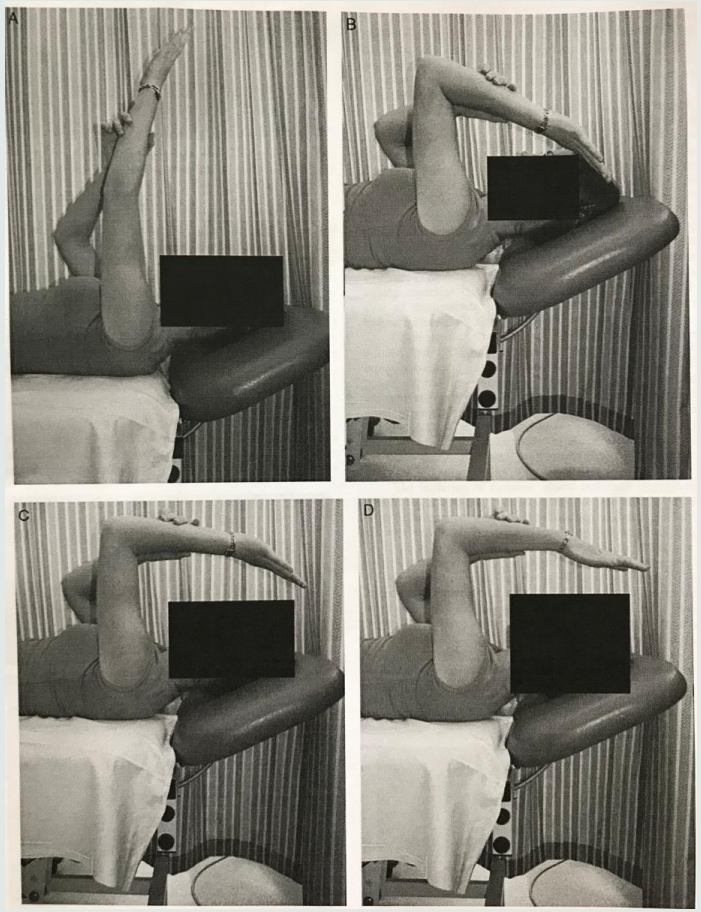

Pipicelli et al, 2011

- Positioning for exercises:
  - Exercises IN SUPINE ONLY with shoulder flexed to 90 degrees, do not allow arm to cross midline as IR/abduction places varus stress on the repaired/injured lateral ligament (increases risk of re-dislocation)
    - With forearm in pronation, perform A/AROM elbow flex/ext but do not exceed 30 degrees of elbow extension (may be less depending on the stability of the joint)
    - Supination/pronation with hand on forehead

PROTOCOL FOR LATERAL ELBOW INSTABILITY: NONOPERATIVE AND OPERATIVE

- Weeks 3-6: IF stability has been determined by the hand surgeon…
  - Splint can be re-molded to 90 degrees of flexion and neutral forearm rotation
  - Exercises move to sitting/standing with pronation/supination at 90 degrees only until cleared by MD to do combined supination/extension
  - Scarring



https://www.avanthimandaleson.com.au/treatment/elbow-instability/



PROTOCOL FOR LATERAL ELBOW INSTABILITY: NONOPERATIVE AND OPERATIVE



Week 4:

Start gentle wrist strengthening (1-2 pounds) and grip strengthening



Week 6-12:

Finish gaining range of motion via joint mobilization, low load prolonged stretching, proximal strengthening, isometrics



Week 12:

Resistive exercises on elbow/forearm with MD clearance

Full extension, supination, and varus forces limited for at least 4 months

Unrestricted activities at 9 months

Proximal strengthening including shoulder ER

TABLE 2. Therapeutic Algorithm for Postoperative Rehabilitation Terrible Triad Injuries

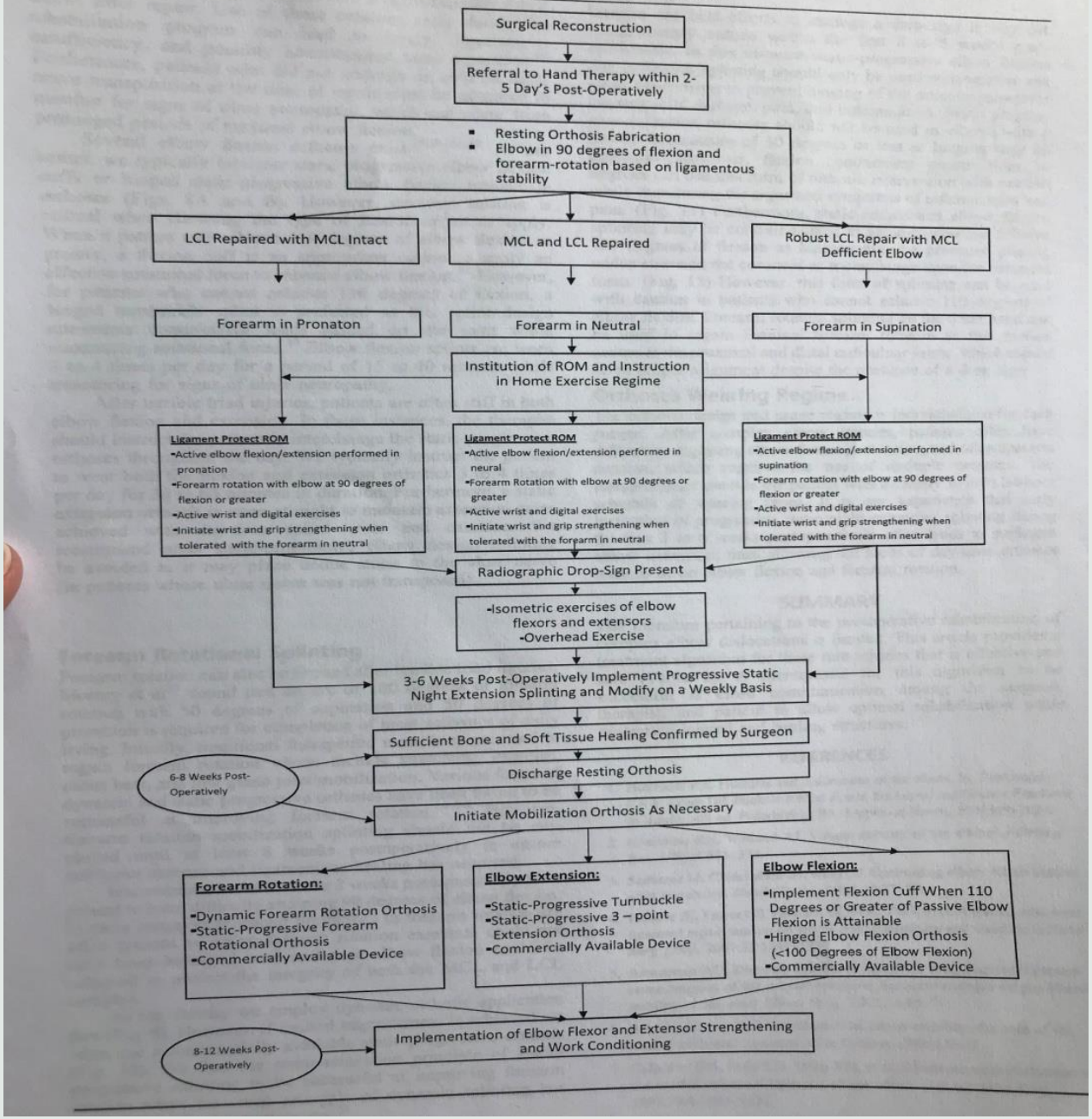

Pipicelli et al, 2011

DROP/SAG SIGN

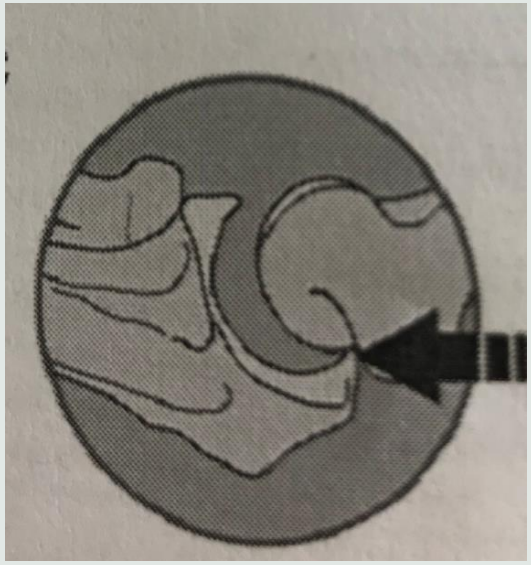

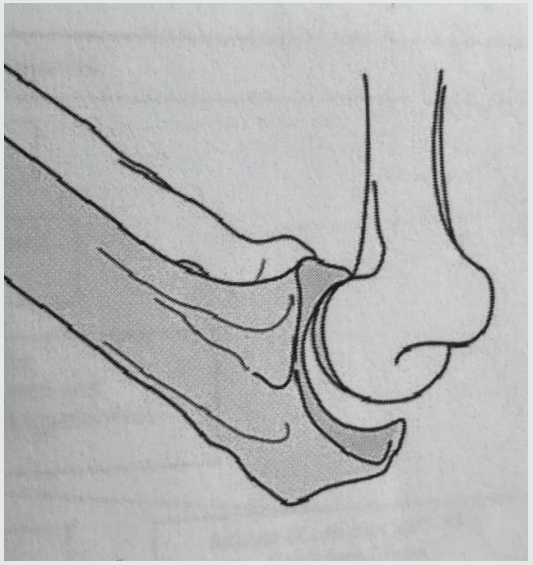



FIGURE 3. A radiographic drop sign is apparent on lateral radiograph. It is an objective, static radiographically measurabl increase in ulno-humeral joint distance.

© 2011 Lippincott Williams & Wilkins

- Indicates underlying humeroulnar instability
- Objective increase of >4mm in ulnohumeral distance which can be seen on x-ray (typical elbow is 2-3mm) (Coonrad et al., 2005).
- If occurs, concern for early joint wear as well as ulnohumeral impingement, pain, and instability

DROP/SAG SIGN

Pipicelli et al., 2012 found that with the overhead protocol in addition to isometric contraction of the brachialis, biceps, and triceps in resting orthosis, the drop sign reduced spontaneously within 2-6 weeks.

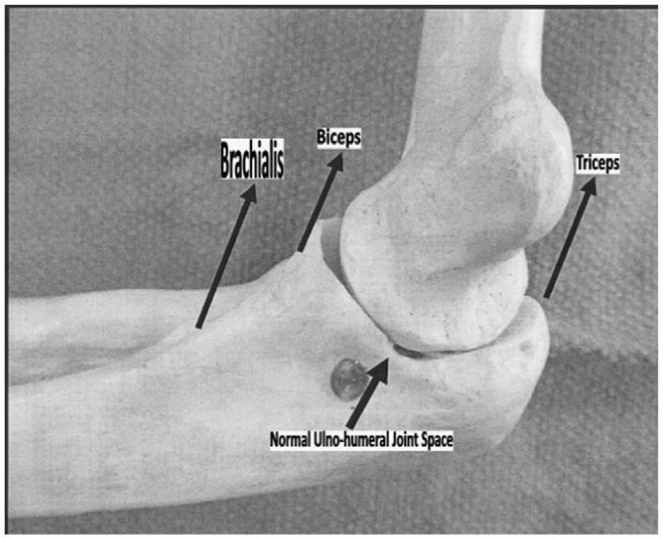

FIGURE 2. *The muscles crossing the elbow joint provide a compressive force, which maintains normal ulnohumeral joint space. When the biceps, brachialis, or triceps contract, the compressive force produced helps stabilize and align the ulnohumeral joint preventing dislocation.*

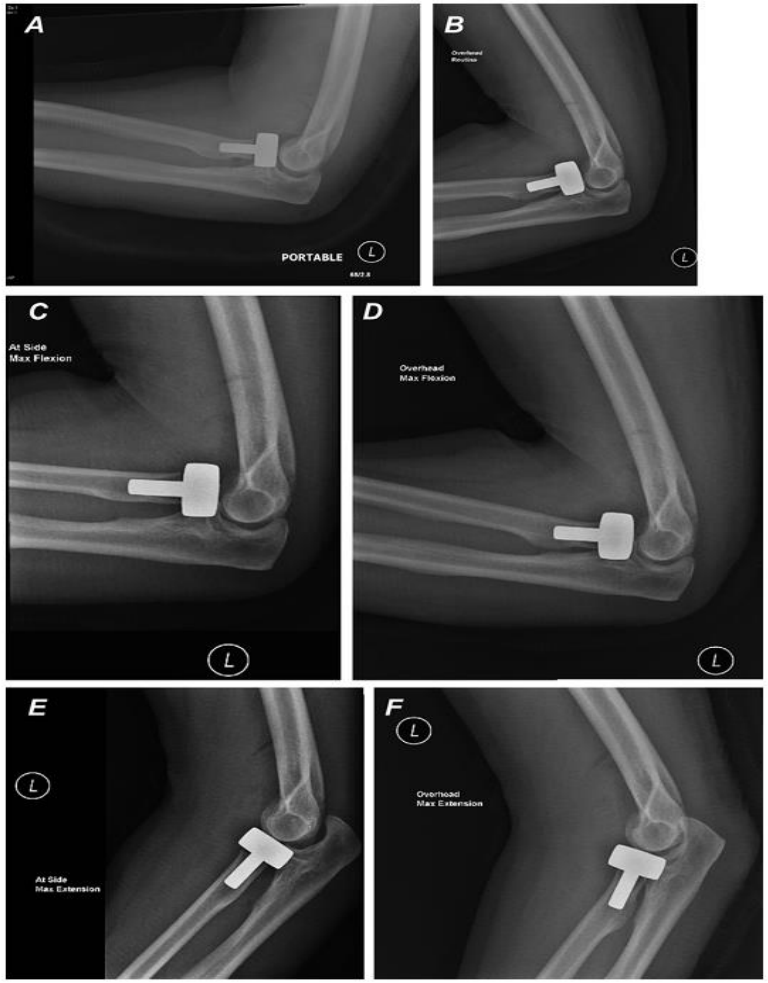

FIGURE 4. *Elbow and forearm range of motion exercises should be performed in an overhead manner in the presence of a radiographic drop sign. Overhead exercises will reduce the gravitational forces to the ulnohumeral joint. Comparison of figures* ***A*** *and* ***B*** *demonstrate that the drop sign is minimized when gravitational forces to the ulnohumeral joint are altered. Figure* ***A*** *is a standard lateral radiograph, whereas figure* ***B*** *is a lateral radiograph in the overhead position.* ***C.*** *Active elbow flexion performed with the elbow at the side increases ulnohumeral joint space and may cause joint hinging/perching especially the coronoid on the articular surface. This will cause pain and inflammation. Furthermore, perching of the coronoid over the articular surface may compromise coronoid fracture healing (especially in the presence of a tenous repair).* ***D.*** *Performing active elbow flexion in an overhead fashion significantly minimizes ulnohumeral joint hinging and impingement.* ***E.*** *Active elbow extension performed with the elbow at the side increases ulnohumeral joint space and causes posterior hinging and shearing of the coronoid.* ***F.*** *Performing elbow extension in the overhead position significantly improves joint alignment and tracking.*

- Szekeres, M., Chinchalkar, S.J. & King, G.J.W., M.D. (2008). Optimizing Elbow Rehabilitation After Instability. *Hand Clinics, 24*, 27-38

- Pipicelli, J.G., Chinchalkar, S.J., Grewal, R., M.D. & Athwal, G.D. (2011). Rehabilitation Considerations in the Management of Terrible Triad Injury to the Elbow. *Techniques in Hand Surgery, 15*(4), 198-208.

- Matthew, P.K., M.D., Athwal, G.S., M.D. & King, G.J.W., M.D. (2009). Terrible Triad Injuries of the Elbow: Current Concepts. *Journal of the American Academy of Orthopedic Surgeons, 17* (3), 137-151.

- Manocha, R. H. K., Banayan, S., Johnson, J. A., & King, G. J. W. (2022). Overhead arm positioning in the rehabilitation of elbow dislocations: An in vitro biomechanical study. *Journal of Hand Therapy, 35*(2), 245–253. https://doi.org/10.1016/j.jht.2022.01.008

THE CURRENT AVAILABLE LITERATURE LARGELY SUPPORTS THE OVERHEAD PROTOCOL

PROS/CONS OF EARLY RANGE OF MOTION PROTOCOLS



Benefits:

- "Early motion nourishes the cartilage and enhances soft tissue healing" (Wolff & Hotchkiss, 2006).
- "Early ROM activities are performed to assist in synthesis, alignment, and organization of collagen tissue" (Aultman, 2011).
- Idea is to improve ROM without compromising stability



Issues:

-Highly unstable elbows may not be appropriate; however, Wolff and Hotchkiss found that "even in highly unstable elbows, a small arc of motion performed passively in clinic BY A THERAPIST several times a week is necessary to prevent significant ROM loss" (pp. 242).

-Insurance

-Compliance or Low Health Care Literacy

CASE STUDY #1

- 64 y/o F s/p GLF in her front yard
  - Comminuted displaced L distal humerus fracture with intercondylar split
  - R hand dominant
  - Primary caregiver for 92 y/o mother with CA
  - <u>Her goals: Basic ADLs and less pain and swelling</u>
  - H/o:
    - Depression/anxiety
    - Scoliosis with multiple falls
    - L shoulder dislocation
    - Osteoporosis
    - HTN
    - High cholesterol

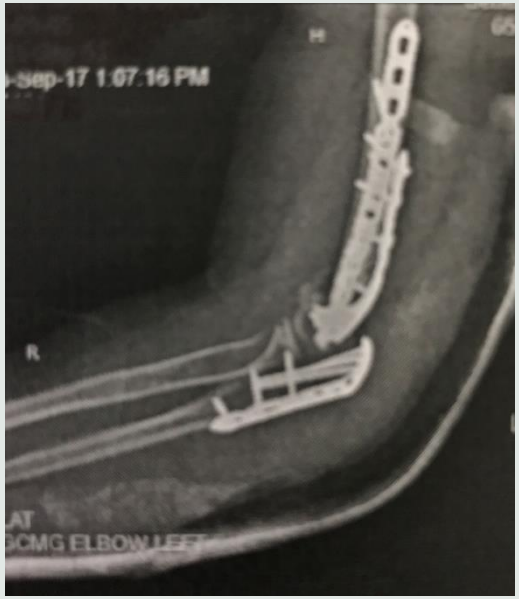



- S/p ORIF and neurolysis and transposition (with subcutaneous sling) of ulnar nerve
  - Five fracture pieces of distal humerus
  - Full elbow range of motion achieved intraoperatively without mechanical block or click or subluxation of ulnar nerve

CASE STUDY #1

- Came to therapy at <u>6 ½ weeks post-op:</u>
  - Plate on lateral epicondyle failed due to lack of bony healing
  - Patient wearing HEB and allowed to perform active range of motion of elbow in brace
  - Patient largely edematous and very painful -> Most important therapy goal at first
  - Plan was to follow-up with referring MD at 2 weeks from OT eval date to determine timing for follow-up procedures including bone graft procedure vs. total elbow replacement

- Therapy weeks 6 ½ -> 10
  - EDEMA CONTROL
    - Coban wraps
    - Tubigrip
    - Overhead elevation and exercise
    - Retrograde massage
  - Function right away to prevent disuse
    - Grasp/release activities including rice, washcloths, cups
  - Education regarding need for continuous motion shoulder/wrist/digits
  - Desensitization
    - Rice
    - Fluidotherapy
  - Patient admits to level of non-compliance at home due to being primary caregiver for her mother.



Patient's best fist at 1st visit

CASE STUDY #1

- Therapy weeks 10-> almost 6 months post initial surgery:
  - Joint mobs to wrist, digits to address stiffness
  - AA/PROM as tolerated; responded better to functional activity with wrist/hand vs AA/PROM
  - Wrist/digit strengthening
  - Ongoing digit dynamic splinting, edema control, functional use of hand, proximal range of motion
  - AROM to her tolerance in HEB
  - Patient using bone stimulator











CASE STUDY #1

- Follow-up Procedure
  - Postoperative dx:
    - L distal humerus lateral epicondyle nonunion with loose hardware
    - L ulnar nerve compression at elbow
    - L elbow contracture with HO
    - L hand PIPJ and thumb MPJ stiffness
  - S/p:
    - Repair of L distal humerus lateral epicondyle nonunion with bone graft
    - Removal of hardware
    - Subcutaneous ulnar nerve decompression
    - L elbow arthrotomy with contracture release of capsule for stiffness
    - L distal humerus osteotomy removal of HO for stiffness

  → <u>30 to 140 degrees of elbow motion achieved in surgery</u>

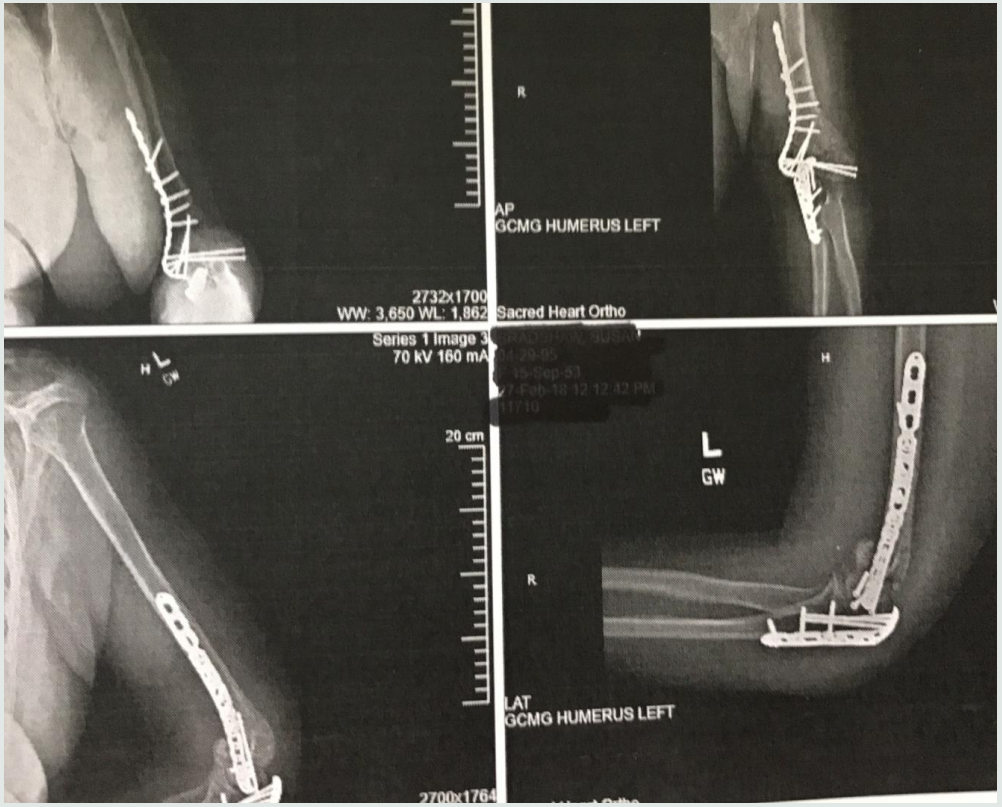

CASE STUDY #1

- Post op day 8 following second procedure
  - Therapy re-initiated for ongoing digit range of motion, edema control
- First post op visit:
  - Goal for as close to operative range of motion 30-140 degree arc of motion as we can get ☺
    - Range of motion in all planes for elbow while watching swelling and ice/tens for pain at wrist/hand
    - 62- 94 arc of motion initially
    - Static progressive device for elbow flex/ext outside of therapy
    - No edema issues with revision surgery
    - Isometrics
    - Working on fluidity of elbow motion within the range of motion that she has
    - FUNCTION
    - Considering pain
    - Guarding/biomechanics
- 3 ½ months post op:
  - Elbow active range of motion 56- 128 degrees
  - Forearm active pronation 60 degrees
  - Forearm active supination 90 degrees
  - Wrist active flexion/ext 40 degrees each way
  - 4.5- 5.0 cm tip to DPC
  - Low pain, starting to use LUE for function with adaptive equipment









CASE STUDY #2

- 42 year old R hand dominant male s/p L elbow LUCL repair, proximal ulna coronoid fixation, radial head ORIF (Terrible Triad)
- No PMH
- Physician
- HIGHLY motivated
- Early referral to therapy with post-op ROM measurement of 62-110 degrees and minimal edema, overhead protocol initiated at first post-op visit at 7 days post-op
- Came into formal therapy, 1-2x/wk x 3 months
  - Progressed from overhead protocol, to regular A/PROM, isometrics, and strengthening including proximal/scapular strengthening
  - Vasopneumatic compression used at the conclusion of every visit
  - He did have a static progressive splint to work with at home
  - Extremely compliant with therapy, never missed
  - Discharged at 3 months -> back to swimming, surfing, and working

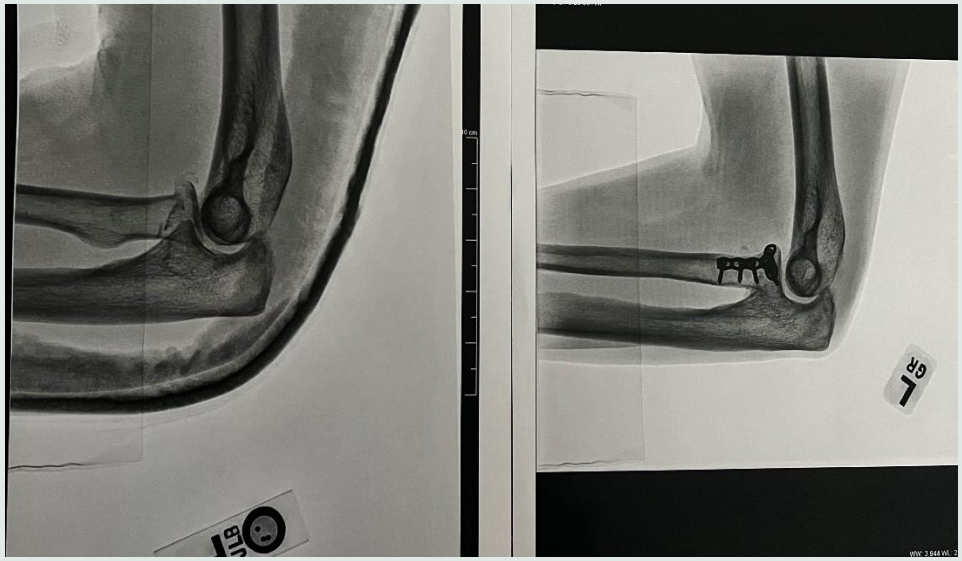

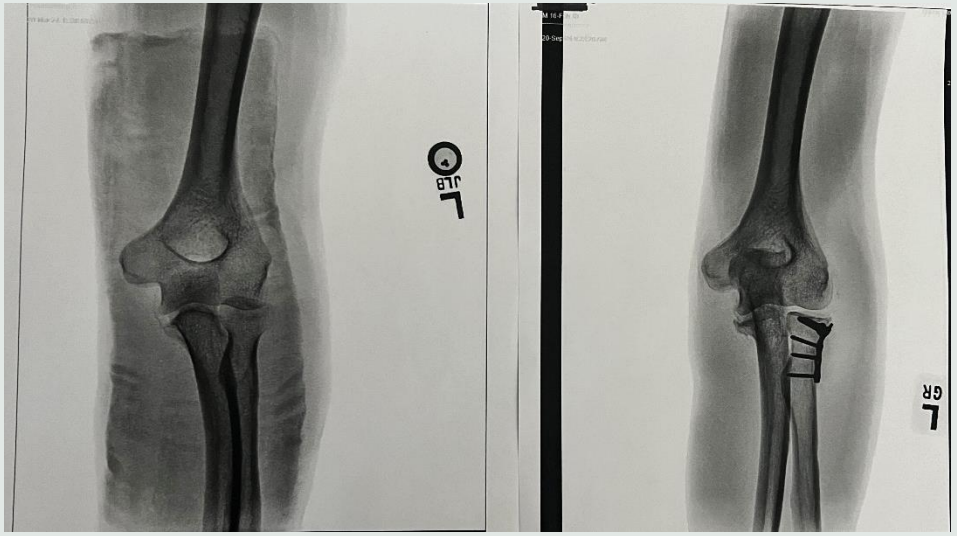

CASE STUDY #2













When therapists discussed with him how difficult this injury is for some patients and asked him what he feel like really helped, he told us that in the first few weeks post-op, he was able to understand what pain was okay with moving and what pain wasn't and that he did push through some of the pain that he knew was okay in the beginning.

CASE STUDY #3

- S/p MCC where he was ejected off of a motorcycle, sustaining multiple BUE fxs/injuries and initially taken to the OR for extensive incision and debridement, ORIF of Left open supracondylar humerus fracture with wound VAC placement, closed treatment of left radial head fracture and incision debridement with skin closure on left lower extremity. Hand surgeon was then consulted and patient is now status post: LUE- CRPP RF/SF MC fxs, secondary closure of L complex elbow wound with rotational BR muscle flap for coverage of lateral elbow defect, brachial artery injury, FPL/all FDS/FCR/PL tendon repairs at musculotendinous junction, L median nerve repair of partial laceration with axogen nerve protector, and open treatment of nondisplaced radial head fracture and humeral supracondylar fracture with intercondylar extension AND R thumb MC CRPP.
- Husband and father of a toddler and his wife was pregnant at the time of his accident and delivered their second baby when patient was approximately 5-6 weeks post-op









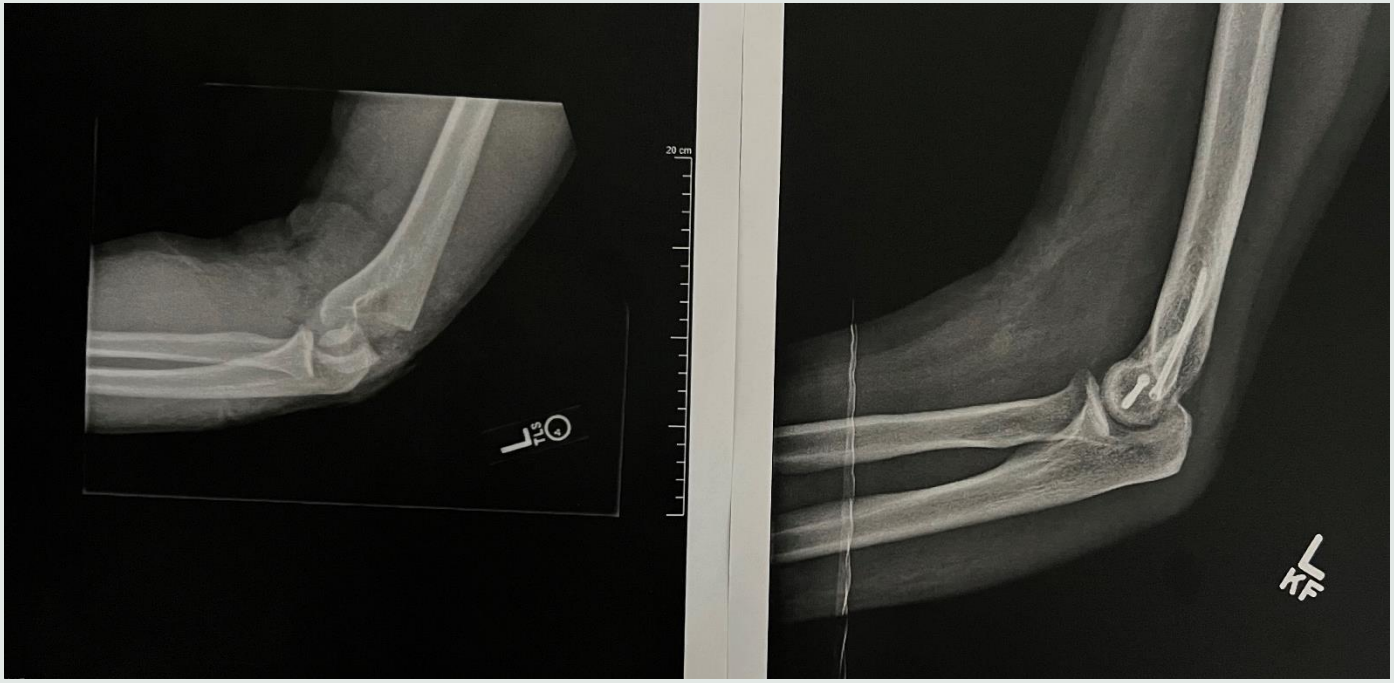

CASE STUDY #3

CASE STUDY #3

- 3 ½ weeks post-op before 1st outpatient therapy appointment, had been hospitalized, and then in inpatient rehab where elbow was immobilized in a cast. Initial elbow ROM: -40/80
- At 3 ½ weeks post-op, was taken out of elbow cast and transitioned to posterior elbow orthosis with therapy initiating shoulder/wrist/hand ROM and gentle AAROM of elbow
- Therapist and surgeon kept in close touch regarding this patient. He was able to wean out of overhead protocol around 6 weeks post-op. MD cleared patient to use static progressive orthosis elbow flex/ext around 10 weeks post-op.
- He was partially compliant with attending therapy due to transportation issues, newborn at home, and transitioning jobs.
- From weeks 6+ post-op, we gradually increased ROM and strengthening activities. Last ROM taken at ~5-6 months post-op: -20/134, grip strength 60# versus 105# on the RUE, and QuickDASH 43.18%.





TREATMENT APPROACH



HEALING TIMEFRAMES

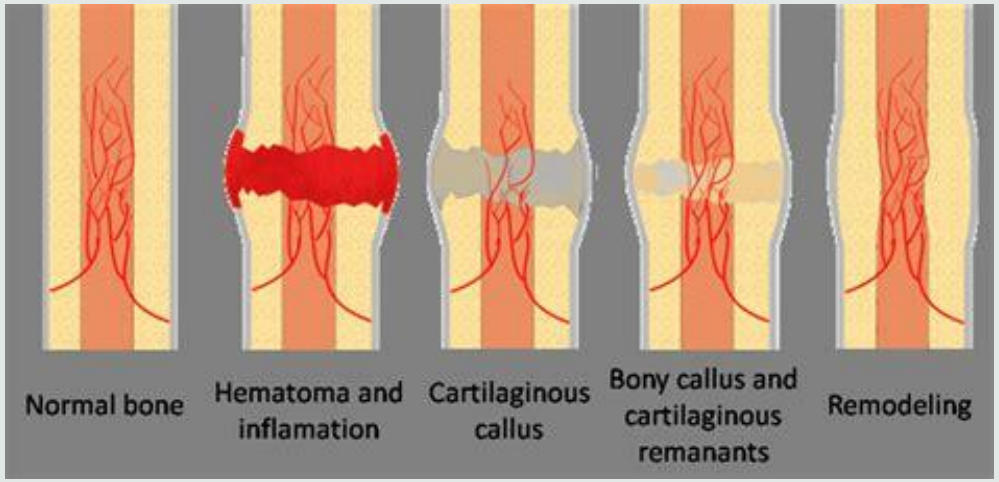

https://www.researchgate.net/profile/Morgan-Chabanon/publication/278827757/figure/fig3/AS:614344635211782@1523482583641/Illustration-of-stages-in-bone-healing-after-a-fracture.png

- Thinking in terms of phases of healing
  - Inflammatory phase (0-2 weeks)
  - Proliferative/Fibroblastic phase (2-8 weeks)
    - Isometric to isotonic exercise with low resistance and high repetitions
    - Introduction of static progressive orthoses (can be introduced in the inflammatory phase for less complex cases)
  - Remodeling phase (2-6 months)
    - Including job or sport specific exercises

EARLY REFERRAL TO THERAPY



- Importance of early referral to therapy
  - Optimal time to start therapy within 1 week of establishing fracture reduction or joint stability
  - Shoulder/scapular control
  - Postural considerations- core?
  - Wrist and hand
  - Assessment of nerve function
  - Edema control
  - Educate patient on compensatory motions
  - Unstable fractures and/or dislocations should begin motion no later than 3 weeks





PATIENT COMPLIANCE AND UNDERSTANDING

- Educating a patient based on their health literacy level is the key to starting to get them to understand why we are doing what we are doing in therapy
- Focus on patient buy-in that the injury is stable enough to move thus risking a stiff elbow is not worth it
- Measuring ROM frequently is crucial in order to make changes in therapy program to continue to advance



HETEROTROPHIC OSSIFICATION

- Heterotrophic Ossification (HO):
  - Formation of organized trabecular bone within and around the elbow which manifests 2-12 weeks following trauma
  - "Associated with open injuries, fractures-dislocations, delayed treatment, excessive soft tissue dissection at the time of surgery, repeat surgical procedures in the early postoperative period, and aggressive passive manipulation of the joint during rehab" (Beredjiklian, 2011)
  - Common sites include the posterolateral aspect of the elbow, LCL, MCL/UCL, and the coronoid process
  - <u>Options: prevent or excise</u>
    - Usually not excised until mature at around 6 months if there is a loss of functional ROM
    - Indomethacin (nonsteroidal anti-inflammatory thus inhibits undifferentiated cells from differentiating into osteoblasts)
    - Low dose radiation in early post-op phase?



chrome-extension://efaidnbmnnnibpcajpcglclefindmkaj/https://abjs.mums.ac.ir/article_7147_b596595d54c93b14f8a30f87b6647b93.pdf

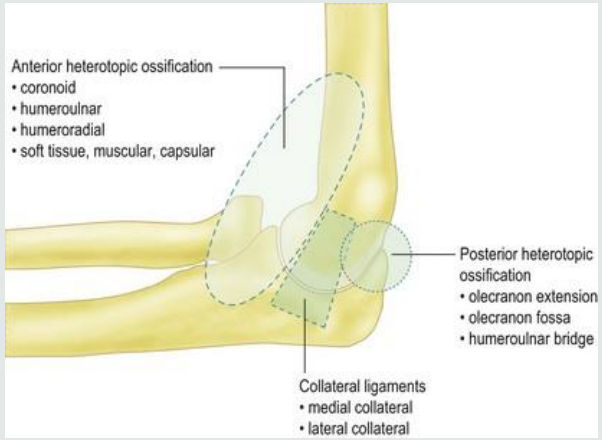

https://musculoskeletalkey.com/wp-content/uploads/2016/09/B978070203099400028X_f028-004-9780702030994.jpg

USE OF ORTHOSES (PER THE LITERATURE)

- Static progressive:
  - Dependent on injury however is often used as soon as incision and fixation can tolerate it – even 1 week post-op if the patient is losing ROM per some of the literature INJURY DEPENDENT (others advocate for 6-8 weeks of healing first; Szekeres et al., 2008)
  - For terrible triad injuries, Consideration for static progressive orthosis at 5 weeks post-op pending healing/MD approval
  - These have been shown to be effective (Davila, 2011) – except with HO
  - Caution with patients who have -30/130 degrees of motion with terrible triad/coronoid fx to prevent hinging
- Dynamic:
  - Spring or elastic for constant stretch
  - Not much research supporting this
  - Poorly tolerated in general by this population
- Static:
  - A nighttime posterior elbow extension splint may be introduced at 3 weeks if the patient stiffens quickly and is having a difficult time extending the elbow (Szekeres et al., 2008)

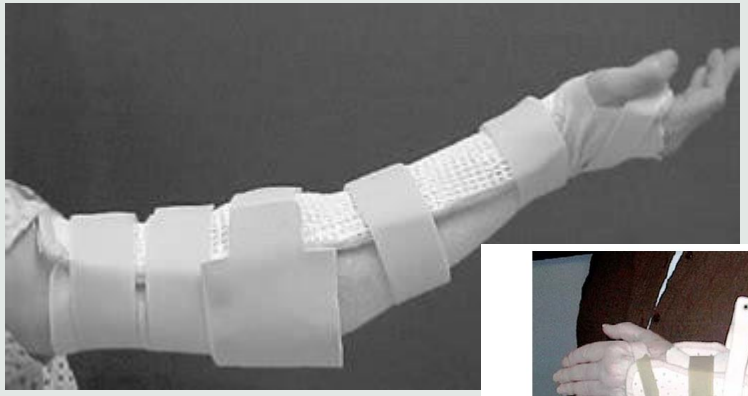

https://musculoskeletalkey.com/wp-content/uploads/2017/03/B9780323033848500135_gr4.jpg

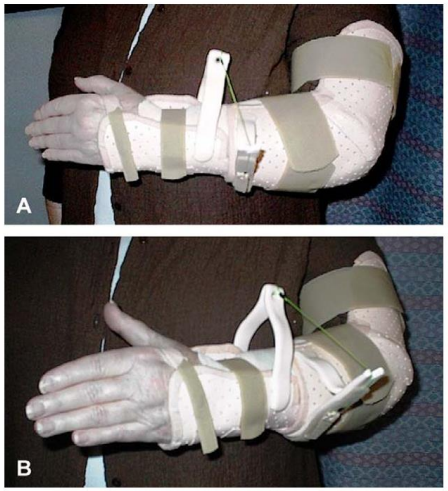

(Davila & Johnston-Jones, 2006)

FIGURE 3. *(A) Static progressive forearm supination splint, lateral view. (B) Static progressive forearm supina-*



FIGURE 1. *(A) Extension turnbuckle splint, medial view. (B) Extension turnbuckle splint, anterior view.*

of pressure. The belly is molded over the antecubital fossa and the posterior elbow strap applies progressive force into extension.[30]

Extension Contracture Splinting

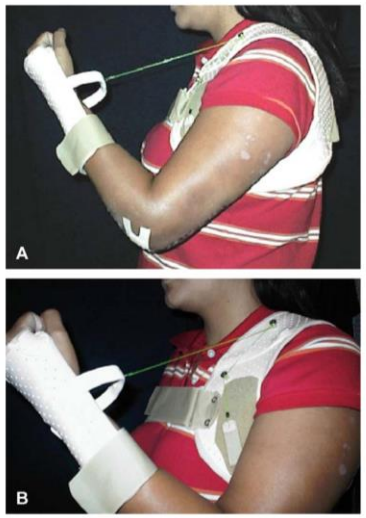

FIGURE 2. *(A) Static progressive elbow flexion splint, lateral view. (B) Static progressive elbow flexion splint, anterior view.*

USE OF ORTHOSES (PER THE LITERATURE): PIPICELLI, ET AL., 2011

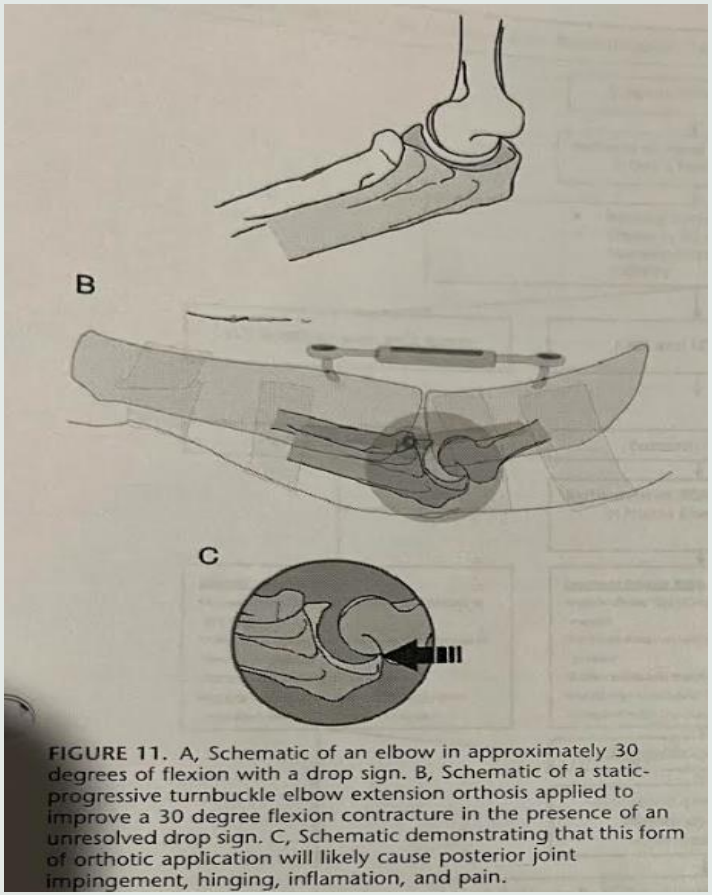

FIGURE 11. A, Schematic of an elbow in approximately 30 degrees of flexion with a drop sign. B, Schematic of a static-progressive turnbuckle elbow extension orthosis applied to improve a 30 degree flexion contracture in the presence of an unresolved drop sign. C, Schematic demonstrating that this form of orthotic application will likely cause posterior joint impingement, hinging, inflamation, and pain.

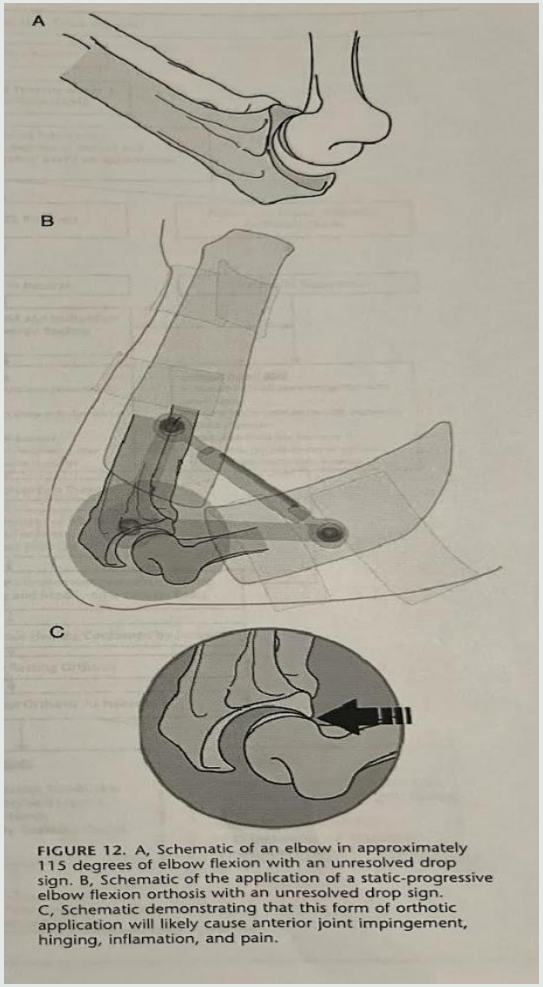

FIGURE 12. A, Schematic of an elbow in approximately 115 degrees of elbow flexion with an unresolved drop sign. B, Schematic of the application of a static-progressive elbow flexion orthosis with an unresolved drop sign. C, Schematic demonstrating that this form of orthotic application will likely cause anterior joint impingement, hinging, inflamation, and pain.

EXAMPLES OF STRENGTHENING IN THE CLINIC











EXAMPLES OF STRENGTHENING IN THE CLINIC

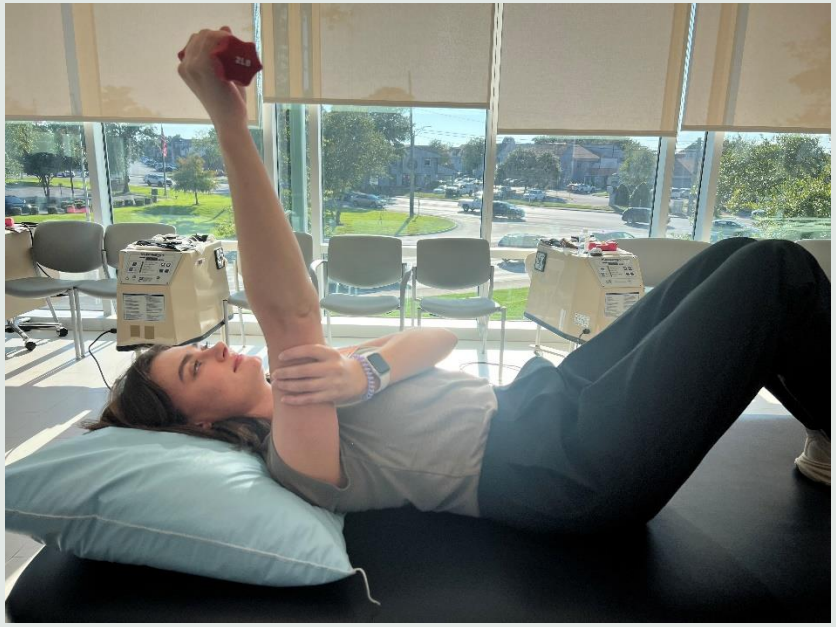



EXAMPLES OF STRENGTHENING IN THE CLINIC





WHAT WORKS IN PRACTICE?

- Whitten, Silfies, Grampurohit, & Fedorczyk (2022) performed a web-based modified Delphi study to identify current therapeutic management of posttraumatic elbow stiffness. They found:
  - Therapists reported orthotic intervention (85%), HEP (82%), PROM (82%), and functional activities (76%) as always or frequently effective in treating traumatic elbow injuries.
  - Therapeutic interventions always or frequently used in clinic were weighted stretch, joint-based mobilizations, PROM, AROM, functional activities, STM, heat with weighted stretch, and mobilization with movement.
  - Low load prolonged stretch was identified by 87% of participants as the most effective intervention
  - No specific orthosis was established as the most effective, which is consistent with the literature
  - High pain rating initially associated with poorer outcome



Journal of Hand Therapy 35 (2022) 299–307

Contents lists available at ScienceDirect

Journal of Hand Therapy

journal homepage: www.elsevier.com/locate/jht

A modified-delphi study establishing consensus in the therapeutic management of posttrauamtic elbow stiffness

Mary Whitten, DHSc, MOT, CHT[a,*], Sheri P. Silfies, PT, PhD[b], Namrata Grampurohit, PhD, OT[c], Jane M. Fedorczyk, PT, PhD, CHT[d]

[a] Drexel University, Bay Path University, VA Connecticut Healthcare System, West Haven, CT, USA
[b] University of South Carolina
[c] Thomas Jefferson University
[d] Thomas Jefferson University

ARTICLE INFO

Article history:
Received 17 February 2021
Revised 30 October 2021
Accepted 13 November 2021
Available online 13 January 2022

Keywords:
Elbow
Posttraumatic stiffness
Orthotic intervention
Clinical reasoning

ABSTRACT

Study Design: : Web-based modified Delphi study.
Background: : Therapy is widely considered the first choice of treatment for posttraumatic stiffness of the elbow since loss of motion is a common sequela following traumatic elbow injuries. There is high variability in practice patterns for the management of the posttraumtic elbow.
Purpose: : The aim of this study is to identify the current therapeutic management of posttraumatic elbow stiffness using expert consensus.
Methods: : This study surveyed experts using a web-based 3 round modified Delphi method. Quantitative data and comments were collected during the first round. Questions with Likert scaling were used to identify consensus (defined as 75% agreement) with each statement and comment boxes enabled open-ended responses to gather expert opinion. Lack of consensus and data from comments guided the second-round of the survey. This process was repeated after Round 2 to develop the Round 3 survey. Consensus was achieved at Round 3 and no further rounds were needed.
Results: : Round 1 included 34 experts (response rate 20%), not all experts were able to continue through all rounds. Round 2 included 18 experts and Round 3 included 15 experts. Survey items were categorized as follows: examination procedures, therapeutic interventions, orthotic intervention considerations, contributing patient factors, and clinical decisions and rehabilitation challenges. Twenty-five percent of items achieved consensus after Round 1, 30% after Round 2 and 52% after Round 3. Although most participants agreed that orthotic intervention is critical to patient outcomes, there were conflicting thoughts about the orthotic design and wearing schedule.
Conclusions: : The findings of this web-based modified Delphi study helped to establish a current body of knowledge using expert consensus to guide practice and identify specific questions that can be studied in future clinical studies on posttraumatic elbow stiffness.

Published by Elsevier Inc.

Introduction

Stiffness is a common complication after elbow trauma, with an incidence ranging from 2% to 89% often impacted by the significance of trauma and prolonged immobilization.[1–3] Loss of range of motion (ROM) at the elbow is difficult to prevent due to the constrained and congruent nature of the elbow, the capsule response to injury, and patient factors contributing to stiffness.[4–7] Once stiffness occurs after trauma normal ROM is rarely restored, and implementation of early rehabilitation is strongly supported for both operative and nonoperative management of elbow trauma.[1,8,9] While implementation of early rehabilitation is supported throughout the literature, there is currently a paucity of evidence that support therapeutic interventions, with variations identified in current practice.[1,8,10,11] Therapeutic interventions for elbow stiffness are briefly described in surgical papers with limited consistency of interventions as well as the episode of care. Currently, there is a lack of identified practice patterns and variability found in non-surgical

* Corresponding author. Drexel University, Bay Path University, VA Connecticut Healthcare System, West Haven, CT, USA
E-mail address: mary.whitten123@gmail.com (M. Whitten).

0894-1130/$ – see front matter Published by Elsevier Inc.
https://doi.org/10.1016/j.jht.2021.11.002





Remember function and your patient's specific goals



WE DON'T ALWAYS GET THE ROM WE WANT..

"Given a choice of adverse outcomes, a stiff elbow is easier to manage than an unstable mobile elbow" (Skekeres et al., 2008).

FUNCTIONAL ROM OF THE ELBOW









Forearm pronation

- Feeding, washing, shaving
- Ideally for ADL/IADL we want at least 50 degrees of pronation

Forearm supination

- Putting objects down, grasping, pushing up from a chair
- Ideally for ADL/IADL we want at least 50 degrees of supination

Elbow flexion

- Feeding, grooming, pulling, lifting
- Ideally for ADL/IADL we want at least 130 degrees of flexion

Elbow extension

- Reaching, pushing, throwing
- Ideally for ADL/IADL we want at least 30 degrees of extension

ADAPTING TO LOSS OF RANGE OF MOTION



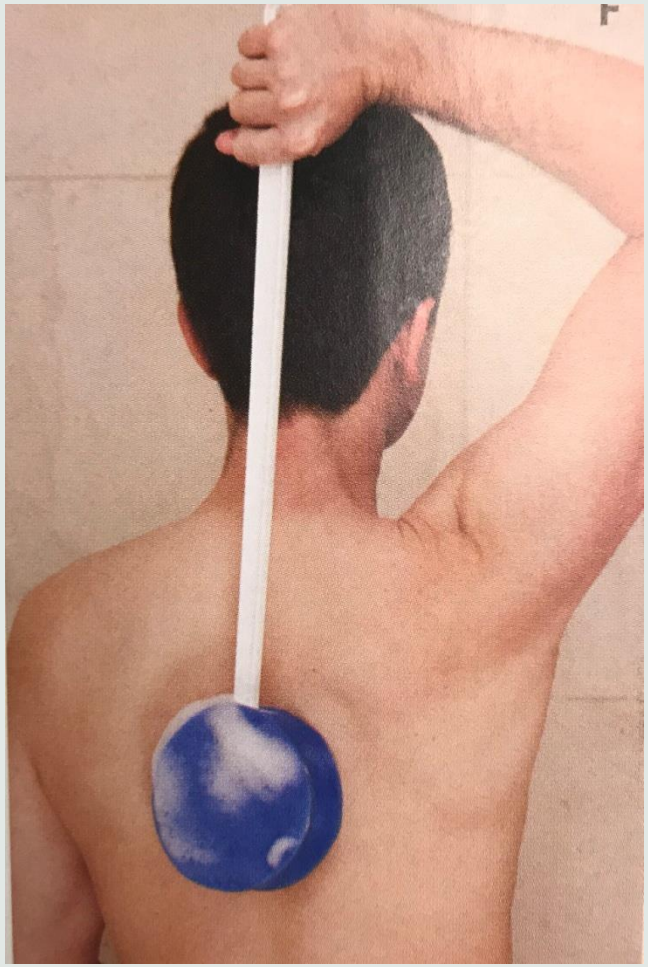



Functional Solutions Catalog

TAKE HOME POINTS

- The successful treatment of elbow trauma in rehab requires a holistic and comprehensive approach. The literature largely supports an approach to elbow rehab based on multiple treatment techniques and this is where we as therapists come in to problem solve for the individual patient to help them meet their goals
- Stability of the elbow is the most important part
- Early referral to therapy is key to maximize mobility in a safe, protected manner with therapist and surgeon direct communication. Correcting faulty biomechanics ASAP is crucial.
- The overhead protocol is supported by the current available body of literature for lateral elbow instability
- Scapular control crucial for successful elbow rehabilitation and we can't forget to evaluate and treat the wrist as these muscles also contribute to stability
- Exercises as tolerated with a priority being avoiding secondary fibrosis from prolonged inflammatory stage and reducing faulty movement patterns/guarding
- When we don't get the ROM we want after severe elbow trauma, it's our job to try to encourage an ideally minimally painless, functional UE, emphasizing to the patient what they can do and ways to adapt with their specific goals in mind

Wall-Paper.co





THANK YOU!







THANK YOU!

- Robert McClellan, OTR/L, CHT, COMT-UE
- Tyler Opitz, DPT, SCS, CSCS, FDNs, FRCs
- Lisa Robertson, OTR/L, CHT
- Vicki McBurney, OTR/L, CHT, CLT
- Kate Birmingham, OTR/L
- Dr. David Fiedler, MD
- Dr. Raymond Noellert, MD
- Dr. Cory Lebowitz, DO
- Dr. Russell Holzgrefe, MD

Thank you to the amazing therapists and surgeons who I am surrounded by who are always willing to share knowledge and collaborate to improve the outcomes of these traumatic injuries.

REFERENCES

1. Altman, E. (2011). Therapist's Management of the Stiff Elbow. *Rehabilitation of the hand and upper extremity* (6th ed., Vol. 2, pp. 1075-1088). Philadelphia, PA: Mosby, Inc.
2. Badre, A., Padmore, C. E., Axford, D. T., Berkmortel, C., Faber, K. J., King, G. J. W., & Johnson, J. A. (2021). The role of biceps loading and muscle activation on radial head stability in Anterior Monteggia injuries: An in vitro biomechanical study. *Journal of Hand Therapy*, *34*(3), 376–383. https://doi.org/10.1016/j.jht.2020.03.012
3. Beredjiklian, P.K. , M.D. (2011). Management of Fractures and Dislocations of the Elbow. *Rehabilitation of the hand and upper extremity* (6th ed., Vol. 2, pp. 1049-1060). Philadelphia, PA: Mosby, Inc.
4. Beredjiklian, P. K., Kachooei, A. R., Gallant, G., Abboudi, J., Kwok, M., Takei, R., & Hotchkiss, R. N. (2023). Abnormal patterns of biceps and triceps co-contraction following elbow surgery may result in elbow stiffness. *The Archives of Bone and Joint Surgery, 11*(6), 398-403. doi:https://doi.org/10.22038/ABJS.2023.64666.3105
5. Bohn, K., Ipaktchi, K., Livermore, M., Cao, J., & Banegas, R. (2014). Current treatment concepts for "terrible triad" injuries of the elbow. *Orthopedics*, *37*(12), 831–837. https://doi.org/10.3928/01477447-20141124-06
6. Broberg, M.A. & Morrey, B.F.: Results of treatment of fracture-dislocations of the elbow. *Clin Orthop Relat Res* 1987; 216: 109-119.
7. Broekhuis , D., Bessems , J.H.J.M. & Colaris, J.W. (2016). Avulsion fracture of the supinator crest as an indication for a sustained posterolateral (sub)luxation of the elbow. A case report, anatomical evaluation and review of the literature. *Orthopaedics & Traumatology: Surgery & Research, 102,* 1113-1116. http://dx.doi.org/10.1016/j.otsr.2016.09.016 1
8. Cannon, N. (2020). *Diagnosis and treatment manual for physicians & therapists: Upper extremity treatment guidelines*. Hand Rehabilitation Center of Indiana.
9. Casavant, A. M., & Hastings, H. (2006). Heterotopic ossification about the elbow: A therapist's Guide to Evaluation and Management. *Journal of Hand Therapy*, *19*(2), 255–267. https://doi.org/10.1197/j.jht.2006.02.009
10. Cohen, M.S., M.D. (2011). Elbow Instability: Surgeon's Management. *Rehabilitation of the hand and upper extremity* (6th ed., Vol. 2, pp. 1134- 1153). Philadelphia, PA: Mosby, Inc.
11. Coonrad, R.W., Roush, T.F., Major, N.M., and Basamania, C.J. The drop sign, a radiographic warning sign of elbow instability. J Shoulder Elbow Surg. 2005; 12:312-7
12. Davila, S.A. (2011). Therapist's Management of Fractures and Dislocations of the Elbow. *Rehabilitation of the hand and upper extremity* (6th ed., Vol. 2, pp.1061- 1074). Philadelphia, PA: Mosby, Inc.
13. Dávila, S. A., & Johnston-Jones, K. (2006). Managing the stiff elbow: Operative, nonoperative, and postoperative techniques. *Journal of Hand Therapy*, *19*(2), 268–281. https://doi.org/10.1197/j.jht.2006.02.017
14. Dodson, J. (n.d.). *Complex Elbow Injuries Part 1 and 2*. *Medbridge*.
15. Fedorcyzk, J., Whitten, M., & Altman, E. (n.d.). ASHT Annual Conference 2023.
16. Frothman, C., Henket, M., Ring, D.C.: Elbow dislocation with intra-articular fracture: The results of operative treatment without repair of the medial collateral ligament. *J Hand Surg (Am)* 2007; 32; 1200-1209.
17. Giannicola, G., Polimanti, D., Bullitta, G. & Sacchetti, F.M. (2014). Critical time period for recovery of functional range of motion after surgical treatment of complex elbow instability: Prospective study on 76 patients. *International Journal of the Care of the Injured, 45*, 540-545. http://dx.doi.org/10.1016/j.injury.2013.11.033
18. Huang, J.I., M.D., Paczas, M., M.D., Hoyen, H.A., M.D. & Vallier H.A., M.D. (2011). Functional Outcome after Open Reduction Internal fixation of Intra-articular Fractures of the Distal Humerus in the Elderly. *Journal of Orthopedic Trauma, 25*(5), 259-265.

REFERENCES

19. Manocha, R. H. K., Banayan, S., Johnson, J. A., & King, G. J. W. (2022). Overhead arm positioning in the rehabilitation of elbow dislocations: An in vitro biomechanical study. *Journal of Hand Therapy*, *35*(2), 245–253. https://doi.org/10.1016/j.jht.2022.01.008

20. Matthew, P.K., M.D., Athwal, G.S., M.D. & King, G.J.W., M.D. (2009). Terrible Triad Injuries of the Elbow: Current Concepts. *Journal of the American Academy of Orthopedic Surgeons, 17* (3), 137-151.

21. McKee, M.D., Veillette, C.J., Hall, J.A., et al. A multicenter, prospective, randomized, controlled trial of open reduction-internal fixation versus total elbow arthroplasty for displaced intra-articular distal humerus fractures in elderly patients. *J Shoulder Elbow Surg.* 2009; 18:3-12.

22. Pipicelli, J.G., Chinchalkar, S.J., Grewal, R., M.D. & Athwal, G.S., M.D. (2011). Rehabilitation Considerations in the Management of Terrible Triad Injury to the Elbow. *Techniques in Hand Surgery, 15*(4), 198-208.

23. Pipicelli, J. G., Chinchalkar, S. J., Grewal, R., & King, G. J. W. (2012). Therapeutic implications of the radiographic "drop sign" following elbow dislocation. *Journal of Hand Therapy*, *25*(3), 346–354. https://doi.org/10.1016/j.jht.2012.03.003

24. Pugh, D.M. & McKee, M.D.: The "terrible triad" of the elbow. *Tech Hand Up Extrem Surg* 2002; 6:21-29.

25. Shaaban, H., Pereria, C., Williams, R, et al. The effect of elbow position on the range of supination and pronation of the forearm. J Hand Surg Eur 2008; 33(1): 3-8.

26. Szekeres, M. (n.d.). *Assessment and Rehab of the Unstable Elbow*. *Medbridge*.

27. Szekeres, M., Chinchalkar, S.J. & King, G.J.W., M.D. (2008). Optimizing Elbow Rehabilitation After Instability. *Hand Clinics, 24*, 27-38. doi: 10.1016/j.hcl.2007.11.005

28. Whitten, M., Silfies, S. P., Grampurohit, N., & Fedorczyk, J. M. (2022). A modified-delphi study establishing consensus in the therapeutic management of posttrauamtic elbow stiffness. *Journal of Hand Therapy*, *35*(2), 299–307. https://doi.org/10.1016/j.jht.2021.11.002

29. . Wolff, A.L. & Hotchkiss, R.N, M.D. (2006). Lateral Elbow Instability: Nonoperative, Operative, and Postoperative Management. *Journal of Hand Therapy.* doi: 10.1197/j.jht.2006.02.008

30. Zeiders, G.J. & Patel, M.K. (2008). Management of Unstable Elbows Following Complex Fracture-Dislocations the 'Terrible Triad" Injury. *The Journal of Bone & Joint Surgery, 90,* 75-84. doi: 10.2106/JBJS.H.00893