

# Long-Term Outcomes in Female Patients With Carpometacarpal Arthroplasty and Metacarpophalangeal Fusion Compared With the Unoperated Side or Carpometacarpal Arthroplasty

Carissa C. Dock, BS,\* Rebecca Stone McGaver, MS, ATC,† Clare K. McCarthy, MD†

**Purpose** Patients with carpometacarpal (CMC) osteoarthritis (OA) often present with metacarpophalangeal (MP) hyperextension and/or thenar atrophy. This study hypothesizes that MP fusion (MPF) performed at the time of CMC arthroplasty (CMCA) for patients who have moderate-to-severe thenar atrophy, MP hyperextension  $>30^\circ$ , or MP arthritis will have greater long-term pinch strength and improvements in the Quick Disabilities of the Arm, Shoulder and Hand (*QuickDASH*) score from preoperative values when compared with the unoperated side or those who had CMCA only.

**Methods** This study involved a retrospective review of long-term results from patients who underwent either CMCA or CMCA/MPF. The *QuickDASH* score, the pain visual analog scale (VAS), and an average of three pinch readings from each thumb were measured on the Baseline pinch gauge and recorded with a correction for hand dominance in right-handed patients.

**Results** Fifty-three female patients with 70 operated thumbs were included in the study. The mean age was 67.2 years. There were 29 CMCA and 41 CMCA/MPFs. The mean follow-up was 6.3 years (range 2–16.9 years). At the latest follow-up, the mean CMCA/MPF pinch strength (11.3 lbs) was significantly stronger than that of CMCA (8.0 lbs) and carpometacarpal osteoarthritis thumbs (8.9 lbs). There was no significant difference in pinch strength between patients who underwent a CMCA and CMCOA thumbs (8.0 lbs vs 8.9 lbs, respectively). Preoperative *QuickDASH* demonstrated worse function in the CMCA/MPF group (55.8 vs 36.5). At the latest follow-up, *QuickDASH* and VAS revealed similar values in both the CMCA/MPF (10.5 and 0.66) and CMCA (18.5 and 0.52) groups.

**Conclusion** Long-term results demonstrate stronger pinch and greater improvement in *QuickDASH* scores in patients who underwent CMCA/MPF compared with those who underwent a CMCA or untreated carpometacarpal osteoarthritis thumbs. (*J Hand Surg Am.* 2023; ■(■):1.e1-e9. Copyright © 2023 by the American Society for Surgery of the Hand. All rights reserved.)

**Type of study/level of evidence** Therapeutic IV.

**Key words** Carpometacarpal arthritis, Carpometacarpal arthroplasty, Metacarpal phalangeal hyperextension, Metacarpal phalangeal fusion, Thenar atrophy.



From the \*University of Minnesota Medical School, Twin Cities Campus, Minneapolis, MN; and the †Twin Cities Orthopedics, Edina, MN.

Received for publication February 8, 2023; accepted in revised form September 13, 2023.

No benefits in any form have been received or will be received related directly to this article.

**Corresponding author:** Clare K. McCarthy, MD, Twin Cities Orthopedics, 4010 West 65th Street, Edina, MN 55435; e-mail: [claremccarthy@tcorn.com](mailto:claremccarthy@tcorn.com).

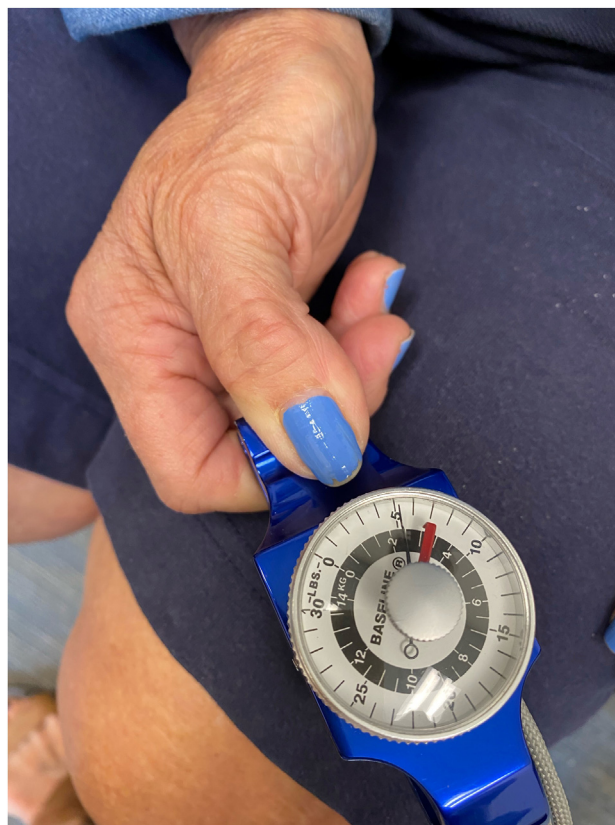0363-5023/23/ ■ ■ -0001\$36.00/0  
<https://doi.org/10.1016/j.jhssa.2023.09.002>

PATIENTS WITH MODERATE-TO-SEVERE thenar atrophy or metacarpophalangeal (MP) hyperextension  $>30^\circ$  have abnormal pinch mechanics at the MP and carpometacarpal (CMC) joints.<sup>1,2</sup> Brand<sup>2</sup> describes the biomechanics of pinch as relying on the adductor pollicis (AP) and flexor pollicis brevis muscles. The abductor pollicis longus (APL), abductor pollicis brevis, and opponens pollicis position the thumb to enable the AP to pinch. Motions of circumduction, opposition, adduction, and abduction all have muscles that cross both the CMC and MP joints, requiring the two joints to act together as a unit.<sup>2</sup> Biomechanical models have similarly identified that the intrinsic tendons stabilize forces across both the CMC and MP joints.<sup>3</sup> Force production in the thumb is nonlinear, and MP instability alters the moment arm of force applied, not only across the MP joint, but also across the CMC joint, resulting in weaker pinch and progressive joint deformity.<sup>4</sup>

When key pinch is evaluated in patients with moderate-to-severe thenar atrophy, the thumb rolls into adduction (Fig. 1), demonstrating that joint stability and equal and opposing muscle forces to balance the CMC and MP joints are necessary for functional pinch mechanics. Smaby et al<sup>5</sup> defined the target pinch force for tetraplegic patients—essentially functional pinch strength—as 31.4 N or 7.06 lbs of key pinch force, the minimum force required to perform activities of daily living, including manipulating a zipper, turning a key, plugging in an electrical cord, and using an automated teller machine.<sup>5</sup>

MP hyperextension  $>30^\circ$  and MP arthritis are established indications for pursuing an MP procedure at the time of CMCA. Eaton and Floyd<sup>6</sup> first suggested hyperextension  $>30^\circ$  as a critical threshold for MP joint management. Blank and Feldon<sup>7,8</sup> recommended arthrodesis for  $>40^\circ$  hyperextension at the MP joint if arthritis was present at the joint or if the joint was not passively correctible, and capsulodesis or sesamoiditis for hyperextension if hyperextension was between  $20^\circ$  and  $40^\circ$ . Brogan et al<sup>1</sup> defined  $30^\circ$  as the hyperextension threshold for an MP procedure because patients with  $<30^\circ$  hyperextension had equivalent functional outcomes to those without MP hyperextension.

Optimal management of the MP joint in patients with CMC arthritis is undefined in the literature. When patients with  $>30^\circ$  MP hyperextension undergo CMCA and experience subsidence, which occurs with all CMCA, the deformity worsens as does hand function.<sup>7,9</sup> No study has addressed stabilization of the MP joint for moderate-to-severe thenar atrophy. The purpose of this study was to compare



**FIGURE 1:** Dysfunctional pinch mechanics. Patient with moderate-to-severe thenar atrophy and CMC arthritis, demonstrating the thumb rolling into adduction during key pinch.

long-term pinch strength, the pain visual analog scale (VAS), and the Quick Disabilities of the Arm, Shoulder, and Hand (*QuickDASH*) scores of patients treated with CMCA/MPF to patients treated with CMCA. We hypothesized that patients undergoing CMCA/MPF for moderate-to-severe thenar atrophy, MP hyperextension  $>30^\circ$ , and/or MP arthritis will have greater long-term pinch strength and improvements in *QuickDASH* scores compared with the unoperated side or those undergoing CMCA.

## MATERIALS AND METHODS

This study was conducted under institutional review board approval. This was a retrospective chart review of long-term results from patients who underwent either a CMCA (a simplified APL suspension performed with a cadaveric fascia lata interposition graft) or a CMCA/MPF (with Stryker EZ clip Nitinol staples and trapezium bone graft) performed by the senior author (C.K.M.) between January 5, 2005 and August 19, 2019.<sup>10</sup> Each patient's medical and surgical history was reviewed, and data (age, sex, hand dominance, X-rays, degree of MP hyperextension,

**TABLE 1. Patient Demographics**

Patient Demographics and Diagnosis	CMCA/MPF	CMCA	CMCOA
Female thumbs	41	29	16
Average age (years)	67.9	68.9	68.3
Age range (years)	53.7–84.3	56.4–79.1	53.7–84.3
Dominant hand	21	16	9
Nondominant hand	20	13	7
Follow-up (years)			
Average	5.8	7.2	
Range	2.1–14.9	2.2–10.9	
Preoperative diagnosis			
STT arthritis (partial trapezoid excision)	9	6	5
MP hyperextension >30°	36	0	10
MP arthritis	10	0	3
Moderate-to-severe thenar atrophy	26	0	8

CMCA, carpometacarpal arthroplasty; CMCOA, carpometacarpal osteoarthritis; MP, metacarpophalangeal; MPF, metacarpophalangeal fusion; STT, scaphotrapeziotrapezoidal.

degree of thenar atrophy, and *QuickDASH* scores) were collected preoperatively, intraoperatively, and from standard postoperative follow-up visits. CMCA/MPF and CMCA patients followed the same postoperative protocol, as described below. Bilateral procedures were never concurrent, ensuring patients would have a functional hand during recovery. carpometacarpal osteoarthritis (CMCOA) thumbs did not receive formal hand therapy. The *QuickDASH* score, VAS, and an average of three pinch strength readings from each thumb were measured on the Baseline pinch gauge (30-pound capacity) and recorded by the senior author or hand therapist at the time of latest follow-up between August 1, 2021 and November 30, 2021. Pinch strength was adjusted based on hand dominance; a correction was applied (pinch strength was divided by 1.15) for procedures done on the dominant hand of right hand-dominant patients to account for the 10% to 18% increase in strength that has been observed.<sup>11–14</sup> No correction was performed for left hand-dominant patients. Objective outcomes were assessed using key pinch, which has been found to have low variability and good reproducibility for patients with osteoarthritis of the hand and allows for consistent analysis when comparing patients with thumb instability, including MP hyperextension and an adduction contracture.<sup>15</sup>

Patients with scaphotrapeziotrapezoidal (STT) arthritis underwent partial trapezoid excision and were distributed equally between the two groups (Table 1). The difference between the surgical groups

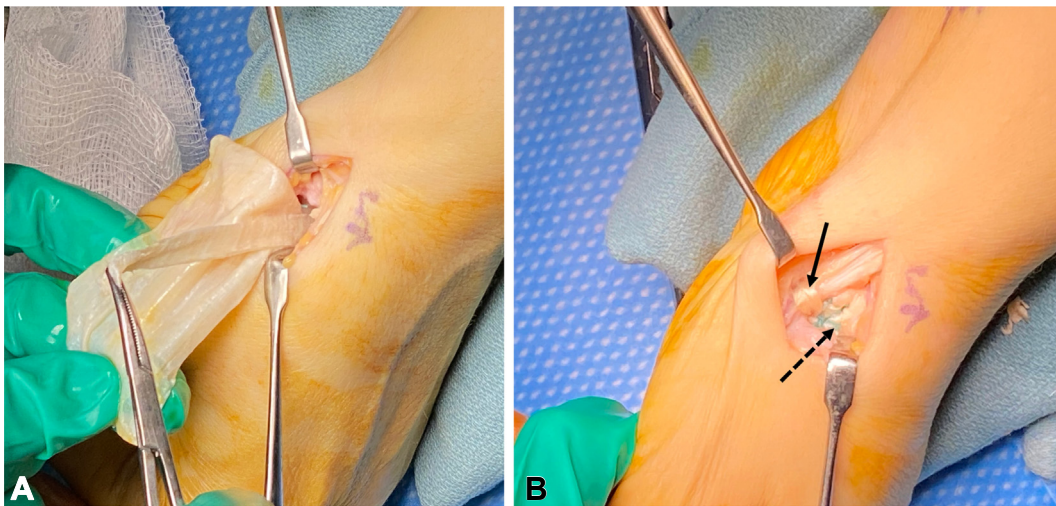
was the presence of MPF. An MPF was performed for the following conditions: MP hyperextension >30°, moderate-to-severe thenar atrophy, or MP arthritis. Some patients had a combination of all three of these conditions. Thenar atrophy was classified as follows: none (no thenar atrophy), mild (isolated area of thenar muscle flattening), moderate (flat thenar muscles), and severe (indentation or concavity of thenar muscles). MP arthritis was defined as bone-on-bone contact in any one of three X-ray views (AP, lateral, and Robert's views).

The inclusion criterion was female patients with Eaton stage III or IV CMCOA treated with CMCA or CMCA/MPF by the senior author. Patients were excluded from final analysis if there was less than 2 years between the final clinical evaluation and their surgery, any additional wrist procedures for arthritis were performed, or a history of carpal tunnel syndrome symptoms or surgery was noted. Contralateral unoperated thumbs were included if they had radiographic evidence of Eaton stage III or IV CMCOA, no history of wrist procedures for arthritis, or history of carpal tunnel syndrome symptoms or surgery.

### Statistical analysis

Sample size calculations were performed to determine the number of patients in each group. To detect a *QuickDASH* difference of 16.9 points (a substantial clinical benefit [SCB] as defined by Hubbard et al<sup>16</sup>) with a power of 0.8, 11 patients would be needed in each group. To detect a VAS pain difference of 2.2 (a





**FIGURE 2:** CMCA surgical technique. **A** The cadaveric fascia lata graft is anchored with an 8-mm slip passed under the FCR and wrapped around itself. **B** The APL suspension sling (dashed arrow) is looped over the remaining APL tendons, and the interposition cadaveric fascia lata graft (solid arrow) is noted.

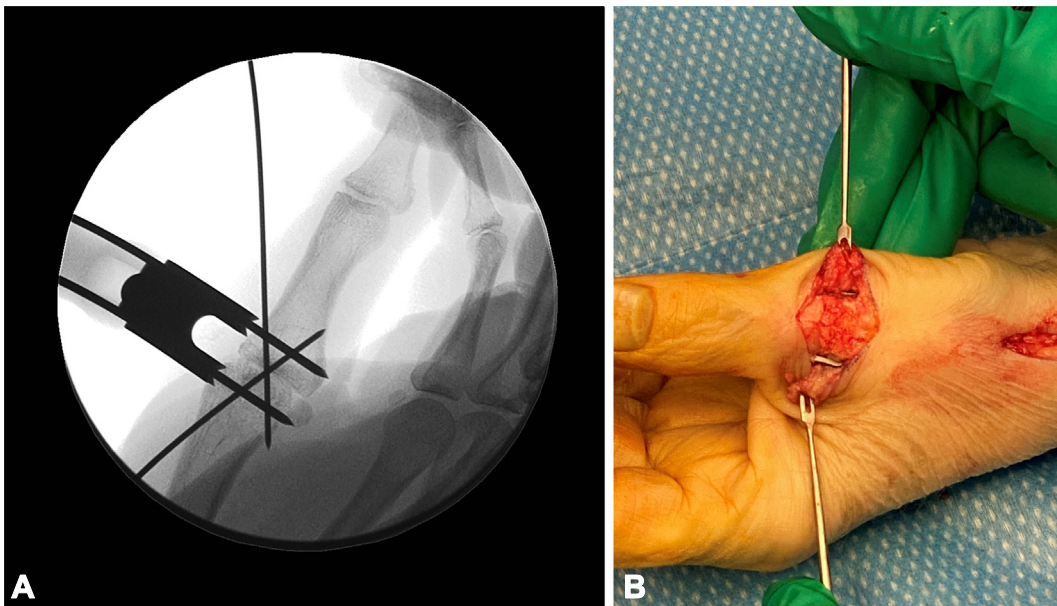
SCB as defined by Randall et al<sup>17</sup>), at least 12 patients would be required in each group. For all other statistical tests, *post hoc* power analysis determined whether statistical testing could be performed. The Shapiro–Wilk test was used to determine if normality could be assumed for the data set. Statistical analysis included Student’s *t* tests to identify statistically significant differences in pinch strength, DASH scores, and VAS scores among the CMCA/MPF, CMCA, and CMCOA groups. A paired two sample *t* test was used to compare patients’ *Quick-DASH* scores obtained preoperatively and at the latest follow-up. Patients who underwent staged bilateral procedures did not have an unoperated contralateral side for comparison. They were analyzed separately, comparing CMCA to contralateral CMCA/MPF. The three patients with bilateral CMCA or bilateral CMCA/MPF were compared to the CMCOA group. For all statistical tests significance was set at  $P < .05$ .

### Surgical technique

**Carpometacarpal arthroplasty.** The CMCA was achieved using an APL slip pulled through the flexor carpi radialis (FCR), wrapped over the remaining three APL slips, and sutured to itself. A cadaveric fascia lata graft was anchored under FCR, rolled up and sutured to itself, and placed into the trapezial space (Figs. 2A and 2B). If STT arthritis was present, 5 to 6 mm of the proximal trapezoid was resected, and bone wax was applied. The joint capsule and the retinacular sheath over the first dorsal compartment were closed with 3-0 Ethibond and 3-0 Vicryl, respectively.

Patients were placed in a postoperative thumb spica surgical dressing for 10 to 12 days. At their first postoperative appointment, patients were given a removable thumb spica splint and exercises to complete three times daily. At the 6-week postoperative appointment, formal occupational therapy was started.

**Metacarpophalangeal fusion.** Patients demonstrated their preferred pinch position in the preoperative holding unit. A surgical marker was used to draw two bisecting lines from the index tip to the thumb tip to guide rotational alignment intraoperatively. A 2-cm longitudinal incision was made over the MP joint and carried down between the extensor pollicis brevis and extensor pollicis longus interval, and the joint capsule was divided. The collateral ligaments were reflected from dorsal to volar with a 15 blade. With the joint exposed, all articular cartilage and hard subchondral bone was removed with a rongeur. To set the fusion position, one 0.045-inch K-wire was introduced retrograde at an angle through the base of the proximal phalanx (to create a cross K-wire for stability), and one was introduced retrograde in the midline of the metacarpal. The fusion was set in 15° to 20° of flexion (27 patients) for those who enjoyed biking, weightlifting, and racquet sports. The fusion was set in 0° of flexion (14 patients) for those who liked fine-pinch activities, including sewing and detail crafts. The wires were then advanced across the joint. The position was confirmed with fluoroscopy, and the trapezial bone graft was packed into the joint space. The radial-sided staple was drilled first so that the staple was not placed dorsal to the



**FIGURE 3:** MP fusion surgical technique. **A** The radial-sided staple is drilled first, and then a 0.062 K-wire was drilled through the guide to the opposite cortex. **B** Intraoperative photo of radial and ulnar staples with collateral ligaments held by retractors and the trapezial bone graft in the joint.

axis of rotation, which could create a hyperextension deformity (Fig. 3A). A 10-mm or 12-mm guide was chosen to span the joint, and a rongeur was used if needed to flatten the bone edges so the guide was perpendicular to the long axis of the metacarpal. A 0.062-inch K-wire was drilled through the guide to the opposite cortex. The proximal cortex only was drilled with the staple set drill bit (by only drilling the proximal cortex, the staple achieved a more solid fixation in the bone without micromotion, allowing for early motion). The ulnar-sided staple was drilled second in the same fashion; this staple could be angled slightly from dorsal to volar to provide solid fixation of the MP joint (Fig. 3B). The capsule was repaired with inverted 3-0 synthetic absorbable sutures, as was the extensor aponeurosis.

Patients were placed in a postoperative thumb spica surgical dressing for 10 to 12 days. At their first postoperative appointment, they were given exercises to do three times daily and two orthoplast splints, including a resting thumb spica splint removed for icing, bathing, and exercises and a small MP-blocking splint to work on interphalangeal joint motion to prevent adhesions. At the 6-week postoperative appointment, X-rays were taken (Fig. 4), and formal occupational therapy was started.

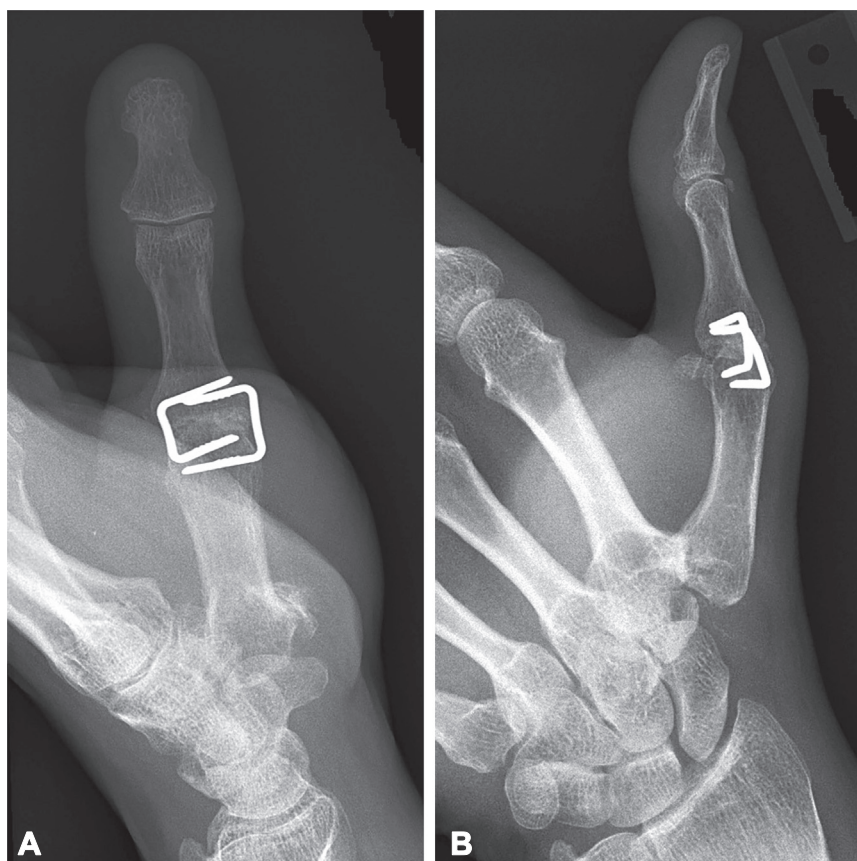
## RESULTS

Fifty-three patients had 70 operated thumbs (41 CMCA/MPFs and 29 CMCA) (Table 1). Seventeen patients underwent staged bilateral procedures (11

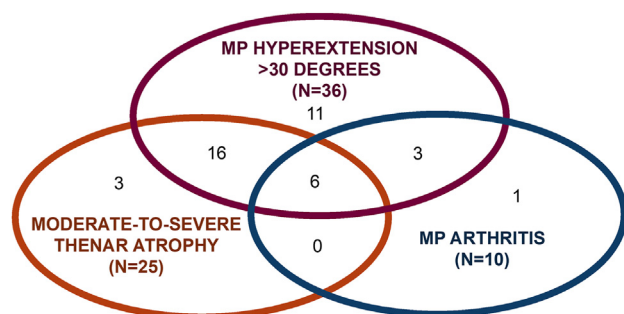
CMCA/MPF and contralateral CMCA, three bilateral CMCA/MPF, and three bilateral CMCA). The mean age was 67.2 years, and the mean follow-up was 6.4 years (range 2.1–14.9 years). Often, patients with MP hyperextension  $>30^\circ$  had concomitant moderate-to-severe thenar atrophy (22/36) or MP arthritis (9/36); six had all three conditions (Fig. 5). Thirty-six patients underwent unilateral procedures; of those, 16 (44%) had an unoperated contralateral thumb with radiographic evidence of Eaton stage III or IV CMC OA. All patients (100%) had complete MP fusion at 6 weeks postoperatively.

Eighteen patients who underwent CMCA (62%) and 28 patients who underwent CMCA/MPF (70%) had preoperative *QuickDASH* scores available. Preoperative *QuickDASH* scores revealed worse patient-reported disability in the CMCA/MPF group preoperatively compared to CMCA (55.8 vs 36.6,  $P < .05$ ) with an SCB of 16.9, this difference is clinically significant.<sup>16</sup> Both groups had statistically and clinically significant improvement from the preoperative value to the value obtained at the latest follow-up for CMC thumbs (36.6 vs 18.5,  $P < .05$ ) and CMCA/MPF thumbs (55.8 vs 8.7,  $P < .05$ ). *QuickDASH* score improvements from preoperative to postoperative results were significantly greater in the CMCA/MPF thumbs compared to CMCA thumbs (47.1 vs 18.1,  $P < .05$ ).

At the latest follow-up, the mean CMCA/MPF pinch strength (11.3 lbs) was significantly stronger than CMCA (8.0 lbs,  $P < .05$ ) or CMCOA thumbs



**FIGURE 4:** Postoperative radiographs for CMCA/MPF fusion. **A** Postoperative AP view shows MP joint fusion and CMCA. **B** Postoperative lateral view shows MP joint fusion and CMCA.



**FIGURE 5:** Preoperative diagnosis for CMCA/MPF patients.

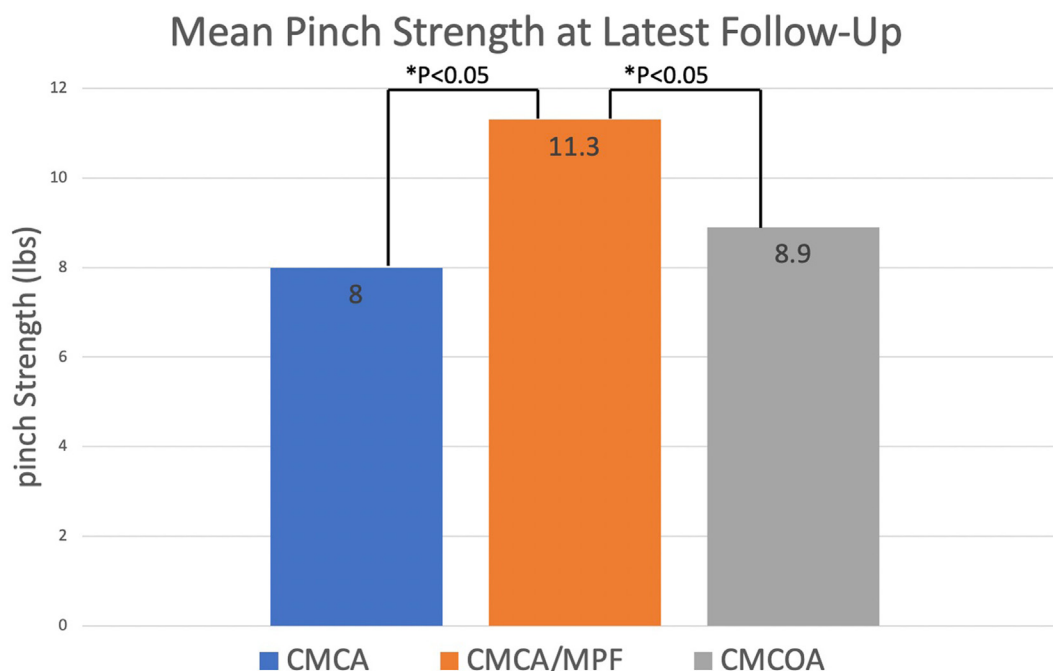
(8.9 lbs,  $P < .05$ ) after correction for hand dominance (Fig. 6). Pinch strength in CMCA and CMCOA thumbs was similar (8.0 lbs vs 8.9 lbs ( $P = .21$ , power = 0.937)). VAS and QuickDASH scores available for all patients at the latest follow-up were similar between CMCA/MPF (0.66 and 10.5) and CMCA (0.52 and 17.6) groups. All groups demonstrated a decline in key pinch strength with age (Fig. 7). There were no patients who underwent CMCA/MPF with  $<7$  lbs of key pinch at the latest follow-up, regardless of age.

Eleven patients underwent CMCA/MPF and CMCA on their contralateral side. The CMCA/MPF was stronger than the CMCA in all 11 patients (Fig. 8). For 16 patients who had an unoperated side with Eaton stage III or IV CMCOA, the CMCA/MPF was 17% stronger than the unoperated side, and the CMCA was 13% weaker than the unoperated side (Fig. 9). Twenty-one (51%) of the 41 CMCA/MPF procedures were performed on the nondominant side.

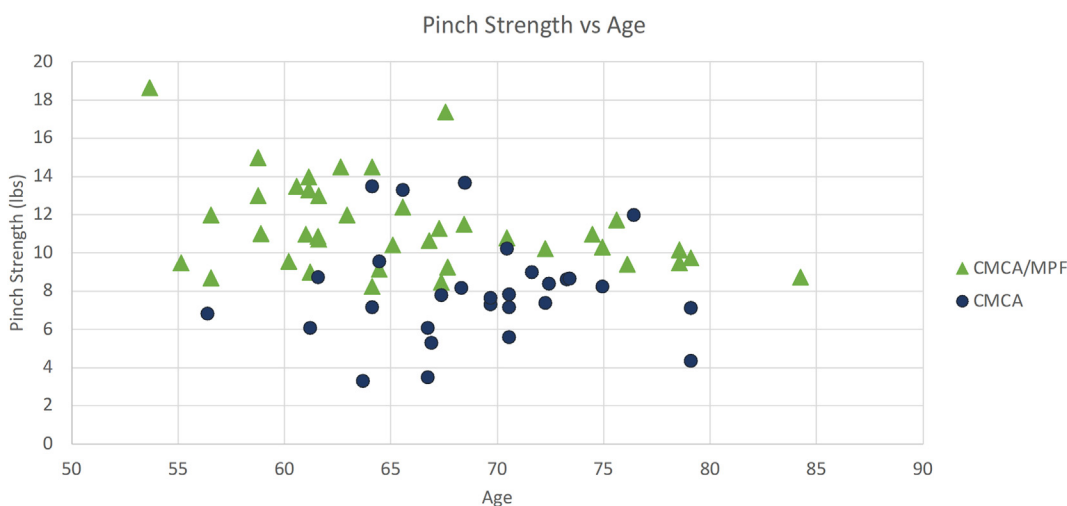
### Complications

In the CMCA/MPF group, three patients were treated with oral steroids for postoperative swelling. In addition, two patients had superficial radial nerve pain that resolved with gabapentin, and one patient had a small finger palsy caused by the regional block resolve spontaneously. In the CMC group, one patient was treated with oral steroids for swelling, two developed trigger fingers and received a steroid injection, one patient had radial nerve pain that resolved with gabapentin, and one patient had continued symptoms from the nerve block resolve spontaneously.





**FIGURE 6:** Mean pinch strength measured at latest follow-up. Here, \* indicates statistical significance.



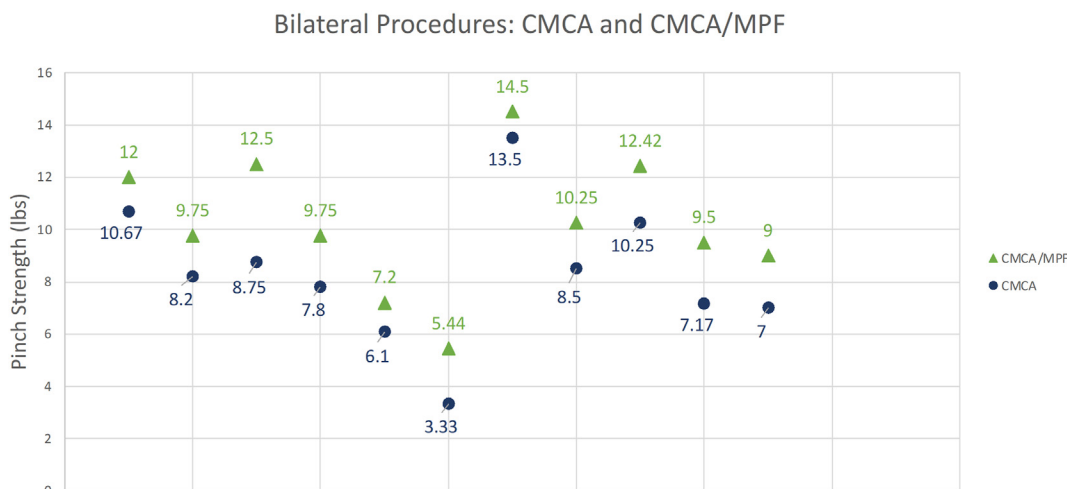
**FIGURE 7:** Pinch strength versus age. All groups experienced a reduction in pinch strength with age, as observed with normative data. Notably, the CMCA/MPF group had no patients with a pinch strength less than 7 lbs.

## DISCUSSION

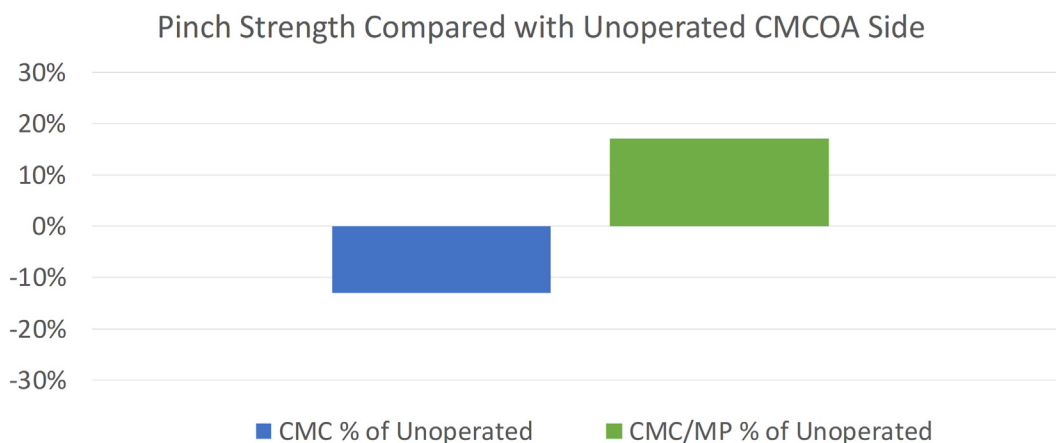
Eaton and Floyd<sup>6</sup> recommended addressing MP hyperextension  $>30^\circ$  and observed that its presence diminishes pinch force and, therefore, “restoration of mechanical efficiency requires stability of both the basal and MP joints with  $>30^\circ$  of hyperextension.” A biomechanical cadaver study demonstrated that for every additional  $10^\circ$  of MP hyperextension, there is a 4.4% decrease in key pinch strength.<sup>18</sup> While the evidence indicates that the MP joint needs to be considered at the time of CMCA, there is a paucity of

literature reviewing the real-life functional outcomes of MP joint management, and no study has addressed the need for MP arthrodesis for moderate-to-severe thenar atrophy.<sup>1,6,19</sup>

The current study demonstrates that patients with pinch strength weakness preoperatively because of either MP hyperextension  $>30^\circ$  and/or moderate-to-severe thenar atrophy who undergo an MP fusion at the time of CMCA ultimately obtain a significantly stronger key pinch than their unoperated side or a CMCA, with long-term strength and stability



**FIGURE 8:** CMCA/MPF and CMCA pinch strength. There were 11 patients in the cohort who underwent bilateral staged procedures with CMCA on one hand and a CMCA/MPF on the contralateral hand. After correction for hand dominance, CMCA/MPF thumbs were stronger (9.6 lbs) than CMCA thumbs (7.8 lbs) at the latest follow-up.



**FIGURE 9:** Pinch strength compared with the unoperated side. When assessed as a percentage of their patients own unoperated side with CMCOA, CMCA/MPF thumbs are 17% stronger and CMCA thumbs are 13% weaker on average.

maintained. Patients undergoing CMCA/MPF have significantly greater improvement in patient-reported outcome measures from the preoperative to postoperative assessments compared to CMCA. Despite worse preoperative function, they achieve satisfactory, functional results similar to patients who only require a CMCA.

Twenty-one percent of revision CMC arthroplasties are reported to require MP stabilization.<sup>20</sup> Postoperative hyperextension  $>30^\circ$ , an adduction contracture, or web space angle  $<30^\circ$  are prognostic factors that lead to poor hand function long-term, hindering key pinch severely.<sup>21</sup> Thus, treating patients most at risk for a poor result based on the presence of preoperative thenar atrophy and/or MP instability may reduce the rate of secondary procedures.

MP fusion procedures in the thumb have traditionally been performed using cross K-wires, interosseous wiring, plates and screws, or minimally invasive compression screws. These procedures can be associated with complications, including pin site infections, hardware removal, tendon adhesions, EPL rupture, and delayed union or non-union, with rates ranging from 20% to 38%.<sup>8,22–27</sup> In our study, an MP fusion was performed with trapezial bone graft and compression staples. Placing the staples radially and ulnarly avoided the complications of prominent hardware, tendon adhesions, and non-union. Patients who underwent CMCA/MPF had no more complications than those who underwent CMCA.

Limitations of this study include the lack of preoperative pinch data. Our conclusions were based on



the comparison with the contralateral hand and thus are not as strong as data comparing the thumb to its preoperative function. Preoperative *QuickDASH* scores were available in 62% of CMCA and 70% of CMCA/MPF, limiting the strength of preoperative comparisons. Preoperative VAS was not recorded; therefore, preoperative to postoperative effects of CMCA and CMCA/MPF on pain could not be assessed. By narrowing the study to females with Eaton Stages III or IV CMCOA, the groups were similar for comparison, but future studies are needed to assess whether the same findings extend to male patients. Lastly, six patients underwent the same bilateral procedures, and a comparison to CMCOA was performed since comparison to the unoperated side was not possible.

In patients with advanced MP instability or moderate-to-severe thenar atrophy, addressing the MP joint with a fusion at the time of CMC arthroplasty adds surgical time, inherent risks and permanent loss of range of motion at the MP joint. However, long-term results show that the thumb is stronger, and the *QuickDASH* and VAS scores of these patients are similar to those having had a CMCA. Future studies will be needed to compare preoperative pinch, patient-reported outcome measures and satisfaction with postoperative function and overall satisfaction to determine whether the addition of pinch strength is clinically significant in this patient population.

## REFERENCES

1. Brogan DM, van Hogezaand RM, Babovic N, et al. The effect of metacarpophalangeal joint hyperextension on outcomes in the surgical treatment of carpometacarpal joint arthritis. *J Wrist Surg.* 2017;6(3):188–193.
2. Brand PW. *Clinical Mechanics of the Hand.* 3rd ed. Mosby; 1999.
3. Cooney WP, Chao EYS. Biomechanical analysis of static forces in the thumb during hand function. *J Bone Joint Surg Am.* 1977;59(1):27–36.
4. Pearlman JL, Roach SS, Valero-Cuevas FJ. The fundamental thumb-tip force vectors produced by the muscles of the thumb. *J Orthop Res.* 2004;22(2):306–312.
5. Smaby N, Johanson ME, Baker B, et al. Identification of key pinch forces required to complete functional tasks. *J Rehabil Res Dev.* 2004;41(2):215–224.
6. Eaton RG, Floyd WE. Thumb metacarpophalangeal capsulodesis: an adjunct procedure to basal joint arthroplasty for collapse deformity of the first ray. *J Hand Surg Am.* 1988;13(3):449–453.
7. Blank J, Feldon P. Thumb metacarpophalangeal joint stabilization during carpometacarpal joint surgery. *Atlas Hand Clin.* 1997;2:217–225.
8. Tonkin MA, Beard AJ, Kemp SJ, et al. Sesamoid arthrodesis for hyperextension of the thumb metacarpophalangeal joint. *J Hand Surg Am.* 1995;20(2):334–338.
9. Li YK, White C, Ignacy TA, et al. Comparison of trapeziectomy and trapeziectomy with ligament reconstruction and tendon interposition: A systematic literature review. *Plast Reconstr Surg.* 2011;128(1):199–207.
10. Sander AL, Buhmann CF, Sommer K, et al. Simplified abductor pollicis longus suspension interposition arthroplasty for thumb carpometacarpal joint osteoarthritis. *Eur J Trauma Emerg Surg.* 2022;48(2):1225–1230.
11. Kawabata H, Demura S, Kitabayashi T. Superior pinch strength in the dominant versus nondominant hand. *Sport Sci Health.* 2013;9(1):7–11.
12. Mullerpatan RP, Karnik G, John R. Grip and pinch strength: normative data for healthy Indian adults. *Hand Ther.* 2013;18(1):11–16.
13. Bohannon RW. Grip strength: a summary of studies comparing dominant and nondominant limb measurements. *Percept Mot Skills.* 2003;96(3 Pt 1):728–730.
14. Petersen P, Petrick M, Connor H, et al. Grip strength and hand dominance: challenging the 10% rule. *Am J Occup Ther.* 1989;43(7):444–447.
15. Ziv E, Patish H, Dvir Z. Grip and pinch strength in healthy subjects and patients with primary osteoarthritis of the hand: a reproducibility study. *Open Orthop J.* 2008;2(1):86–90.
16. Hubbard JC, Zhang Y, Qiu Y, et al. Establishing the substantial clinical benefit in a non-shoulder hand and upper extremity population for the *QuickDASH* and PROMIS upper extremity and physical function computer adaptive tests. *J Hand Surg Am.* 2022;47(4):358–369.e3.
17. Randall DJ, Zhang Y, Li H, et al. Establishing the minimal clinically important difference and substantial clinical benefit for the pain visual analog scale in a postoperative hand surgery population. *J Hand Surg Am.* 2022;47(7):645–653.
18. Harold R, Henning P, Smetana B, et al. The effect of thumb metacarpophalangeal hyperextension on thumb axial load and lateral pinch force in a cadaver model of thumb trapeziectomy and flexor carpi radialis suspensionplasty. *J Hand Surg Am.* 2023 Feb 22; S0363-5023(22)00720-1.
19. Poulter RJ, Davis TRC. Management of hyperextension of the metacarpophalangeal joint in association with trapeziometacarpal joint osteoarthritis. *J Hand Surg Eur Vol.* 2011;36(4):280–284.
20. Munns JJ, Matthias RC, Zarezadeh A, et al. Outcomes of revisions for failed trapeziometacarpal joint arthritis surgery. *J Hand Surg Am.* 2019;44(9):798.e1–798.e9.
21. Moineau G, Richou J, Liot M, et al. Prognostic factors for the recovery of hand function following trapeziectomy with ligamentoplasty stabilisation. *Orthop Traumatol Surg Res.* 2009;95(5):352–358.
22. Agout C, Bacle G, Brunet J, et al. Chronic instability of the thumb metacarpophalangeal joint: seven-year outcomes of three surgical techniques. *Orthop Traumatol Surg Res.* 2017;103(6):923–926.
23. Swaisi M, Igeta Y, Pavalache R, et al. Arthrodesis of the thumb metacarpophalangeal joint: conventional open technique with a locking plate or compression pins versus minimally invasive technique with compression pins or screws. *Hand Surg Rehabil.* 2019;38(3):174–178.
24. Day CS, Ramirez MA. Thumb metacarpophalangeal arthritis: arthroplasty or fusion? *Hand Clin.* 2006;22(2):211–220.
25. Eiken O. Palmaris longus-tenodesis for hyperextension of the thumb metacarpophalangeal joint. *Scand J Plast Reconstr Surg.* 1981;15(2):149–152.
26. Hagan HJ, Hastings H. Fusion of the thumb metacarpophalangeal joint to treat posttraumatic arthritis. *J Hand Surg Am.* 1988;13(5):750–753.
27. Lutsky KF, Edelman D, Lebowitz C, et al. Union rates and complications after thumb metacarpophalangeal fusion. *Hand.* 2019;14(6):803–807.